

Content available at: <https://www.ipinnovative.com/open-access-journals>

IP International Journal of Forensic Medicine and Toxicological Sciences

Journal homepage: <http://www.ijfmts.com/>

Case Report

A clandestine affair – A case report

R. Varun Kumar^{1,*}, Abhijit Subhedar¹

¹Dept. of Forensic Medicine and Toxicology, Osmania Medical College, Hyderabad, Telangana, India



ARTICLE INFO

Article history:

Received 20-08-2023

Accepted 12-09-2023

Available online 25-10-2023

Keywords:

Ante mortem ligature mark

Saliva dribble mark

Hesitation cuts Contusion on inner surface of scalp

ABSTRACT

According to the witnesses, crime scene and inquest report, deceased is a 30 years old female, found dead lying on floor, in her apartment house along with a male, who was found hanging from a ceiling fan in the same room. The deceased body was brought to Mortuary, Osmania General Hospital at 04:00 PM on 28/01/2023 by the Investigation Officer and requested for postmortem examination under section 174 Criminal Procedure Code. The postmortem findings were an antemortem horizontally placed ligature mark at the level of thyroid cartilage in the front of neck, internally there was an inward fracture of tip of greater horn of hyoid bone on the right side with surrounding tissue contusion. There were some small crescent shaped abrasions noted on both sides of front of neck which were suggestive of nail marks. There was a contusion over the inner surface of the scalp. With meticulous crime scene investigation and post mortem examination and interpretation of the findings cause of death was given as “Ligature Strangulation”

This is an Open Access (OA) journal, and articles are distributed under the terms of the [Creative Commons Attribution-NonCommercial-ShareAlike 4.0 License](https://creativecommons.org/licenses/by-nc-sa/4.0/), which allows others to remix, tweak, and build upon the work non-commercially, as long as appropriate credit is given and the new creations are licensed under the identical terms.

For reprints contact: reprint@ipinnovative.com

1. Introduction

Asphyxia is exclusion of air from lungs.¹

According to mechanism of production.¹

1.1. When exclusion of air from lungs is by ligature around the neck, and

1. Constriction force of ligature is weight of the body “Hanging”.
2. Constriction force of ligature is anything other than the weight of the body “Strangulation”.

1.2. When exclusion of air from lungs is by any means other than ligature around the neck “Suffocation”.

1.3. Classical signs are asphyxia are¹

1. Cyanosis

2. Congestion of internal organs

3. Petechial haemorrhages

4. Oedema

5. Engorgement of the right side of the heart

6. Increased fluidity of the blood

Types of strangulation¹

2. Case

On 28th of January, 2023, we received an inquest from Station house office of Adibatla police station of Hyderabad city police division. As per the police inquest, at around 12:30pm on the same day, a male and a female were found dead in an apartment. A male was found hanging from a ceiling fan (Figure 1) and female was found dead lying beside male (Figure 2). Crime scene was slightly disturbed and the entry door was left open. Empty alcohol bottles, glasses and food packets were present in the crime scene.

* Corresponding author.

E-mail address: varun.cmchr@gmail.com (R. V. Kumar).



Fig. 1: Deceased male hanging from the ceiling fan.



Fig. 2: Deceased female found dead lying beside.

Table 1: Strangulation is mostly homicidal, followed by suicidal and accidental¹.

S. No	Ligature used	Type of strangulation
1.	Traditional ligature (rope, cloth, wire etc)	Ligature strangulation [most common; classical strangulation]
2.	Hands	Throttling (manual strangulation)
3.	Palm	Palmar strangulation
4.	Bend of elbow	Mugging
5.	Executioner's cord	Garroting
6.	Two pieces of bamboo	Bandsola




Fig. 3: Possible ligature material present in the crime scene




Fig. 4: Alcohol bottles in crime scene

3. Postmortem Findings

Body was wrapped in green and blue colour fleece blanket. Body was dressed in white and orange colour floral designed chudidhar top, blue colour legging pant and yellow colour bra (Figure 5). Three orange colour glass bangles were present around left wrist. Body was in supine position, eyes and mouth were closed. Saliva dribble mark present on the right side of face. Mild discolouration of lips and finger nails were noted (Figure 6). Scalp hair are black in colour. Red colour nail polish applied to all the nails of both foot. Multiple old healed horizontal linear scars, present over front of left forearm (Figure 7) {suggestive of old hesitation cuts}. Old healed horizontal surgical scar of size 12cm x 1.5cm, present 10cm below umbilicus {suggestive of lower segment caesarean section}. Post mortem lividity seen at the back of the body and is fixed. Rigor mortis present all through the body.



Fig. 5: Clothes of the deceased.

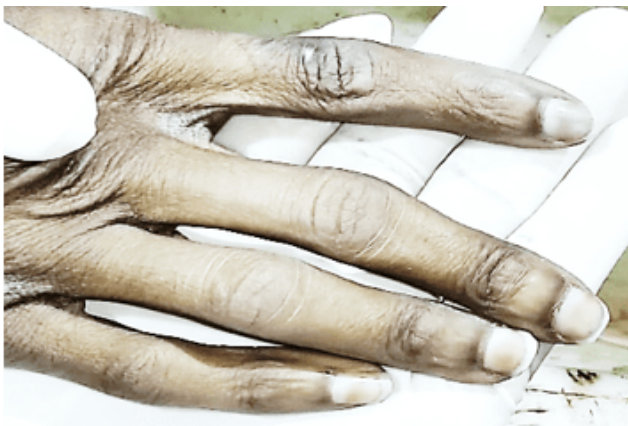

Fig. 6: Mild bluish discolouration of finger nails.

A horizontally placed non continuous antemortem patterned {grooving in between} pressure abrasion {ligature mark} (Figures 8, 9 and 10) of length 26cm with a width of 1cm was placed over the front and sides of the neck on the thyroid cartilage in the middle. The ligature mark was reddish brown in colour and parchmented. Internally there was an inward fracture of tip of greater horn of hyoid



Fig. 7: Old healed and healing hesitation cuts over front of left forearm.

bone on the right side with surrounding tissue contusion (Figures 11 and 12) and thyroid cartilage was intact.

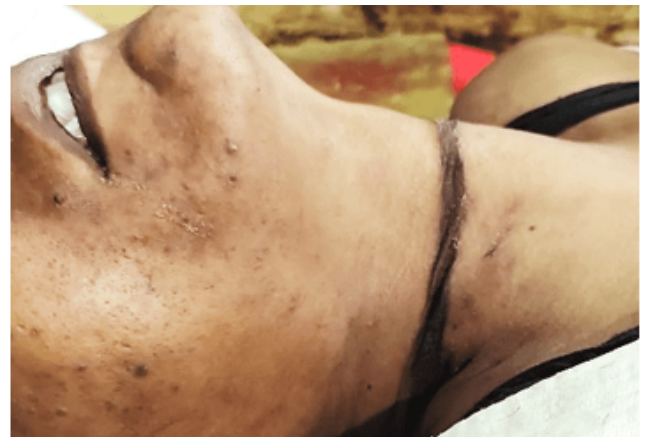

Fig. 8: Horizontal ligature mark

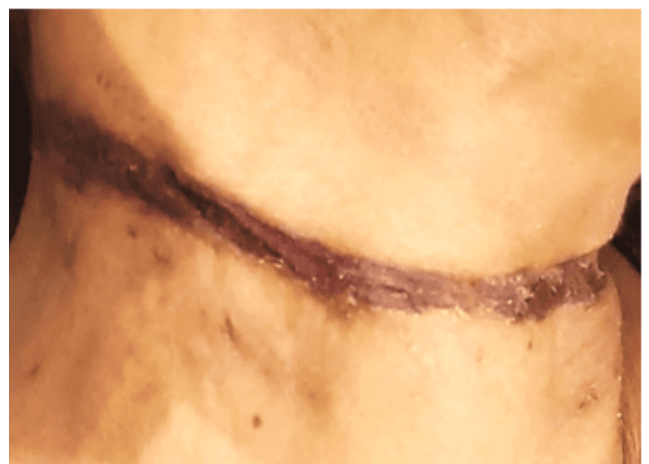

Fig. 9: Grooving pattern in between

On reflection of scalp, a contusion of size 6cm x 4cm, present over right occipitoparietal region of inner surface of scalp and bone correspondingly (Figure 13). On opening the skull cavity, brain is congested and oedematous (Figure 14).

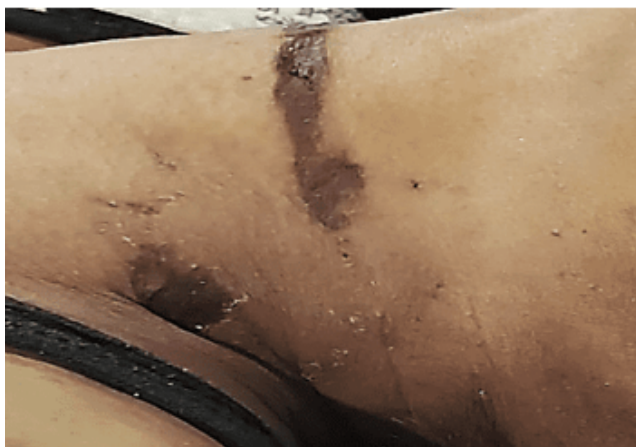

Fig. 10: Noncontinuous pattern

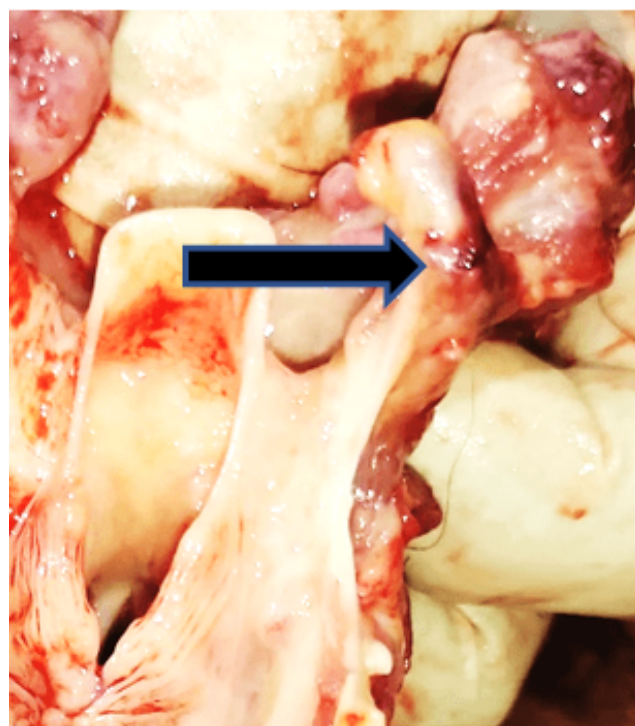


Fig. 12: Inward fracture of greater horn.

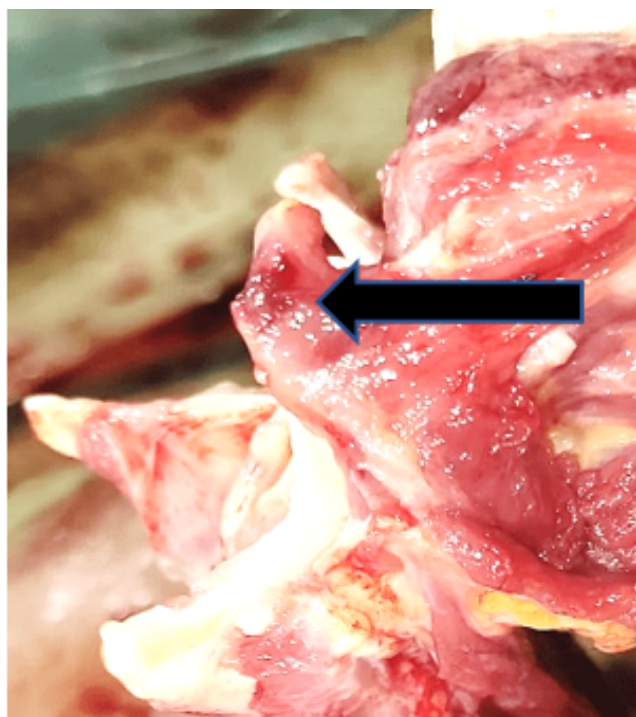


Fig. 11: Surrounding tissue contusion around fracture site.

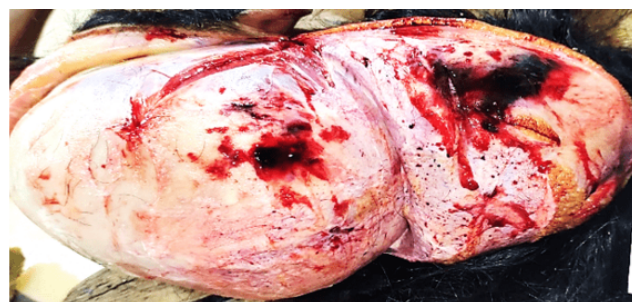

Fig. 13: Contusion over right occipitoparietal region

All the internal organs were congested and no other findings particular to cause of death in this case. Stomach contents were about 20ml of straw colour fluid with some semi digested rice food was present with non-specific smell, mucosa was mildly congested and hence preserved along with routine viscera for chemical analysis and alcohol was found to be present in the chemical analysis by Telangana State Forensic Science Laboratory.

Cause of death was opined as “Ligature Strangulation”.

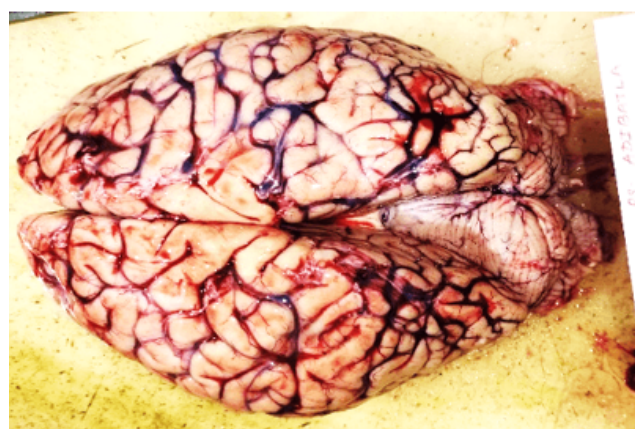


Fig. 14: Congested and oedematous brain.

4. Discussion

In this case, there were two deaths happened in the same premises, one male was found dead hanging from a fan which is clearly suggestive of antemortem hanging as the cause of death. But the other deceased who was found dead lying in the same room with a non-continuous patterned ligature mark in her neck with no intact ligature material around her neck and with slightly disturbed crime scene creates doubt, whether the cause of death in the second case is because of hanging or strangulation.

1. These kinds of cases also need meticulous crime scene investigation and psychological autopsy along with routine autopsy to arrive at the manner, mode and cause of death.
2. Psychological autopsy in this case was done with neighbours of that society and few friends of the deceased male. According to them, this female was married to another male and has 2 children in that marriage, currently she was separated and living alone in this house. She had acquaintance with this deceased male, they used to meet often, have drinks and intimate sexual relationship, recently they had frequent fights as he got doubts that she was in similar relationship with other men as well.
3. The multiple old healed horizontal linear scars present over front of left forearm, which were suggestive of old hesitation cuts, also suggests that she had suicidal tendencies which might have developed because of the continuous mental trauma she had because of the frequent fights between them.
4. In the entire crime scene only these electric wires (Figure 3) corresponds to the ligature mark present over the neck in the body of the deceased female. The grooving pattern of the ligature mark well corresponds with the electric wires.
5. The contusion in the inner surface of scalp might have been produced during the struggle, hence can be considered as defence injury¹.
6. Usually, the ligature mark in homicidal strangulation cases used to be completely encircling the neck with crossing over pattern of the ligature mark¹. But in this case, it was non continuous, which can be substantiated by the loose long hair of the deceased female which might have interrupted the ligature material and the skin.
7. Adultery in general can be understood as ‘Sexual intercourse between a married person and someone else other than the spouse, i.e. a person who is not his/her wife/husband’.
8. As per section 13 (1)(i) of the Hindu Marriage Act, 1955, if a spouse “has, after the solemnization of the marriage, had voluntary sexual intercourse with any

person other than his or her spouse” it can be a ground for divorce².

9. Section 10 (1)(i) of Indian Divorce Act 1869³ and Section 27 (1)(a) of the Special Marriage Act, 1954 also provide adultery as one of the divorce grounds⁴.
10. As per section 497 of Indian Penal Code, 1860, “Whoever has sexual intercourse with a person who is and whom he knows or has reason to believe to be the wife of another man, without the consent or connivance of that man, such sexual intercourse not amounting to the offence of rape, is guilty of the offence of adultery, and shall be punished with imprisonment of either description for a term which may extend to five years, or with fine, or with both. In such case the wife shall not be punishable as an abettor”.⁵
11. It may be noted that this section has been struck down by the hon’ble Supreme Court in Joseph Shine v. Union of India, 2018.⁶
12. Science students find the statement familiar that “every action has an equal and opposite reaction” (Newton’s law of motion). While extra marital affair is the sharpest weapon against the other spouse. Marriage is a forever concept in India. Seeing other people while you are married is against societal norms. Extra marital affairs brutally stir the foundation of marriages.
13. Adultery laws in India no longer hold the act a criminal offence
14. Except for Muslim laws, all other religious and secular marriage and divorce laws provide adultery as a ground for divorce.
15. After decriminalisation of adultery, some higher courts in India have upheld extra marital affairs of husband as cruelty against wife. However, there is no established rule in this regard and matter depends upon the particular facts of the case.
16. National crime records bureau gives the statistics that in 2020 out of 29193 murders happened in India, 1588 murders were because of illicit relationships which was about 5.43 percentage.⁷ And in 2021 out of 29272 total recorded murders, 1559 were due to illicit relationship which amounts to 5.32 percentage.⁸

5. Ethical Clearance

Taken from Institutional Ethics Committee, Osmania medical college.

6. Source of Funding

None.

7. Conflict of Interest

None.

References

1. Aggrawal A. *APC Forensic Medicine and Toxicology for MBBS*. 2nd ed. and others, editor. Avichal Publishing Company; 2019. Available from: https://www.amazon.in/Forensic-Medicine-Toxicology-MBBS-Aggrawal/dp/8177394916#detailBullets_feature_div.
2. The Hindu Marriage Act, 1955. India Code: Section Details [Internet]. www.indiacode.nic.in. Available from: https://www.indiacode.nic.in/show-data?actid=AC_CEN_3_20_00004_195525_1517807318992§ionId=38579§ionno=13&orderno=13.
3. The Divorce Act, 1869 _____ Arrangement Of Sections _____ Preamble [Internet]. . Available from: <https://www.indiacode.nic.in/bitstream/123456789/2280/1/A1869-04.pdf>.
4. The special marriage act, 1954. 1. India Code: Section Details [Internet]. . Available from: https://www.indiacode.nic.in/show-data?actid=AC_CEN_3_20_00019_195443_1517807321908§ionId=30186§ionno=27&orderno=28.
5. Section 497 Indian Penal Code, 1860. India Code: Section Details; Available from: https://www.indiacode.nic.in/show-data?actid=AC_CEN_5_23_00037_186045_1523266765688§ionId=46284§ionno=497&orderno=560.
6. Case Analysis: Joseph Shine v. Union of India - Indian Law Portal [Internet].; 2020. Available from: <https://indianlawportal.co.in/case-analysis-joseph-shine-v-union-of-india/>.
7. Available from: <https://ncrb.gov.in/sites/default/files/CII%202020%20Volume%201.pdf>.
8. Available from: https://ncrb.gov.in/sites/default/files/CII-2021/CII_2021Volume%201.pdf.

Author biography

R. Varun Kumar, Post Graduate Student

Abhijit Subhedar, Professor and HOD

Cite this article: Kumar RV, Subhedar A. A clandestine affair – A case report. *IP Int J Forensic Med Toxicol Sci* 2023;8(3):112-117.