



Content available at: <https://www.ipinnovative.com/open-access-journals>

IP International Journal of Forensic Medicine and
Toxicological Sciences

Journal homepage: <http://www.ijfmts.com/>



Case Series

Challenges presented by decomposition in medico-legal autopsies-A case series

Kandhimalla Ambica^{1*}, Taquiuddin Khan¹

¹Dept. of Forensic Medicine, Osmania Medical College, Koti, Hyderabad, Telangana, India



ARTICLE INFO

Article history:

Received 09-11-2023

Accepted 11-12-2023

Available online 19-01-2024

Keywords:

Adipocere

Differential Decomposition

Mummification

Skeletonization

ABSTRACT

Decomposition is a natural process which turns complex organic elements into simpler forms. The changes brought in by the decomposition is still a hurdle even in this era of evolvement of advanced scientific techniques. Conditions like existence of differential decomposition in the same cadaver might confuse an inexperienced forensic pathologist. Interdisciplinary approach like by using forensic entomology and histopathology plays an important role while dealing the cases with advanced decomposition changes. Yet some times the results might lead us to a blind end in achieving few of the objectives of a medico-legal autopsy. The two cases in this discussion presents different decomposition changes and the hurdles posed by them.

This is an Open Access (OA) journal, and articles are distributed under the terms of the [Creative Commons Attribution-NonCommercial-ShareAlike 4.0 License](#), which allows others to remix, tweak, and build upon the work non-commercially, as long as appropriate credit is given and the new creations are licensed under the identical terms.

For reprints contact: reprint@ipinnovative.com

1. Introduction

Decomposition is a phenomenon through which complex organic components of previously living organism gradually separate into even simpler elements. The process of decomposition starts within few hours after the death. The main objectives of a medico-legal autopsy are:

1. To make positive identification of the deceased in case of an unknown,
2. To determine the time since death, cause, manner and modes of death and
3. To detect the external and internal injuries present over the body.

Cadavers presenting with varying degrees of decomposition hampers the assessment of these objectives during autopsies.

Problems at autopsy due to decomposition have existed since the very first forensic investigations were

undertaken and persist to this day, even with the development of sophisticated adjuncts to traditional autopsies such as computerized tomography and magnetic resonance imaging. Although newer techniques may provide alternative ways of viewing bodies, organs and tissues, the artifacts induced by putrefaction and autolysis still require interpretation.¹

It is often difficult to handle decomposed bodies due to fluid accumulation, insect activity, artefacts resembling injuries. Despite a prosecutor's best efforts, it must be recognized that there is always the risk that alteration of postmortem tissues by these processes may potentially compromise and/or confuse evaluations.¹ Here are the 2 cases in which advanced decomposition posed difficulties to ascertain these objectives.

2. Case 1

An unknown male body has been brought by railway police to Osmania general hospital mortuary in a state of advanced moist decomposition. Inquest states that they found the body in between bushes in an isolated area away from the railway

* Corresponding author.

E-mail address: ambica.geetha@gmail.com (K. Ambica).

track and there is no disturbance in the crime scene. Case is filed under 174 section of Criminal Procedure Code. On external examination, deceased is a male of height 160cms. Clothes present around the body are discoloured and soiled with foul smelling decomposition fluids (Figure 1). Maggots of different sizes are crawling over the body (Figure 4). Skull and face are skeletonized. Orbits are empty and post-mortem dislocation of teeth are present Neck structures are disintegrated leaving the bony and cartilagenous structures behind. Chest & Abdominal areas are skeletonised exposing the ribs and vertebrae (Figure 2) A transparent thoracotomy tube is found in the right 5th intercostal space. Internal organs of thoracic & abdominal region turned black, mushy and are in the process of disintegration. Body cavities are filled with foul-smelling dark decomposition fluids. Skin over the limbs and genital areas is intact, turned black and superficial layer is peeled off.

1. Facial features, skin complexion, moles/scars cannot be made out. Tailor mark is absent over the clothes. A tattoo mark is present over the inner surface of right forearm (Figure 3 B). Finger prints are intact and have been preserved (Figure 3 A). Skeletal muscle tissue has been sent for toxicological and DNA analysis.
2. The body is found in an open area with loose clothing giving access to free air, insects and bacteria which hastened the putrefaction. Even though it is rainy season the temperature is high which favoured the growth and activity of the insects. The voracious feeding larvae of blow flies (Diptera: Calliphoridae) measuring 12mm in length are present in masses in all the body cavities.
3. The necrophagous species provide the information of greatest evidential value because of their direct and obligatory association with the body. Of greatest forensic importance in this group are the blowflies (Diptera: Calliphoridae) because they are usually the first group to colonise a body and are found in greatest numbers, consequently they can provide the most accurate information regarding the minimum time-since-death (Greenberg, 1991).²
4. Maggot age and development can give a date of death accurate to a day or less, or a range of days, and is used in the first few weeks after the death.³The first instar is approximately 5 mm long after 1.8 days, the second instar is approximately 10 mm long after 2.5 days, the third instar is approximately 17 mm long after 4-5 days. Based up on the length and structure, the maggots are in between second and third instar stages. The approximate time since death given in this case is 4-5 days prior to post-mortem examination.
5. The in-situ thoracotomy tube in the body indicates the presence a pre-existing infection or fluid/blood collection and increased moisture content inside the thoracic cavity which speeds up the putrefaction.

6. But by the time body has been brought to mortuary most of the soft tissue is lost and visceral organs turned into black soft masses making it difficult to correlate the internal injuries with external injuries. Opinion as to the cause of death in this case has been kept pending initially.



Figure 1: Body skeletonized with disintegration of scalp and skin over trunk with exposed skull and ribcage.



Figure 2: Softened blackish internal organs in the process of disintegration.




Figure 3: a: darkened skin over right upper limb with intact finger prints. b: intact tattoo mark over the inner aspect of right forearm.



Figure 4: Masses of maggots crawling over the body.

3. Case 2

A 34-year-old male body has been brought to Osmania general Hospital mortuary. As per the inquest, deceased was a construction worker who migrated from other state few months back to Hyderabad. A missing complaint has been filed about him few weeks back and the body was found in an isolated area in a forest. Id card was found inside the shirt pocket.

On external examination, body is partially skeletonized (Figure 5). There is differential decomposition presentation in this body, with both mummification in the upper half and adipocere in the lower half (Figure 8). Skull is partially skeletonized with thick leathery scalp, Skin over face and chest is disintegrated (Figures 6 and 7). Orbits are empty, neck structures are disintegrated. Mandible is separated from the skull. Soft tissue is lost resulting in dismembered and haphazardly present limbs. Skin over the abdomen is brown, dry, leathery and shrivelled, Viscera is converted into hard black mass with loss of normal anatomical separation

(Figure 8).

Over the pelvic region there is adipocere formation with tissue being soft, yellowish greasy wax like in consistency. There is a line of demarcation between abdomen and pelvic regions with mummified and adipocere tissues being separated from each other (Figure 9). Vertebrae and all the limb bones are exposed.

Larval of hide beetle (*Dermestes maculatus*) of sizes 0.5cm to 0.75cm and pupae few adult forms are present over the body (Figure 10). Left foot and right hand are absent. Lower 1/3rd of left tibia is having a irregular but precisely cut margin (Figure 11). The ends of right fore-arm lower 1/3rd is irregular (Figure 12). The 3rd molar tooth has been sent for DNA analysis.



Figure 5: Mummified partially skeletonized dismembered body.

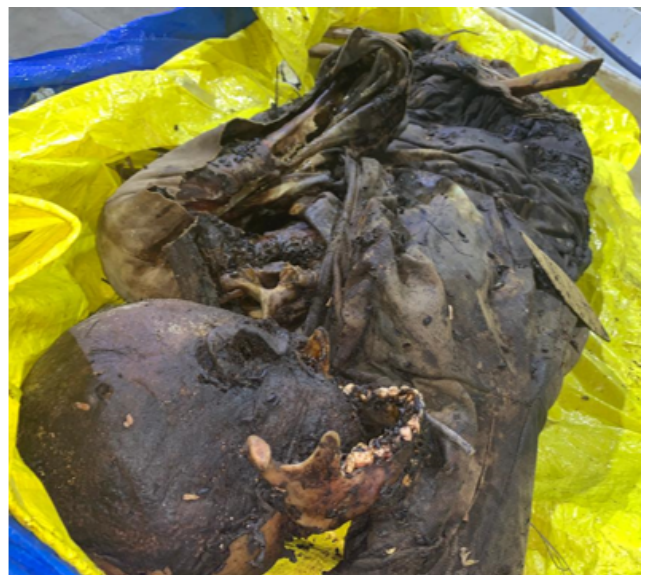

Figure 6: Scalp hair is lost and scalp became thick leathery. Mandible is separated due to disintegration of soft tissue.

1. Body is covered by thick full sleeves jacket which prevents access to free air and provides a warm environment which supports mummification. Features in mummified bodies are commonly well preserved, but in this case loss of skin over the face and neck,



Figure 7: Skin over the face and neck and other soft tissues are disintegrated exposing ribs and vertebrae.




Figure 9: Yellowish greasy wax like adipocere tissue in the pelvic region. Arrow indicating the line of demarcation. Differential decomposition in the same body.

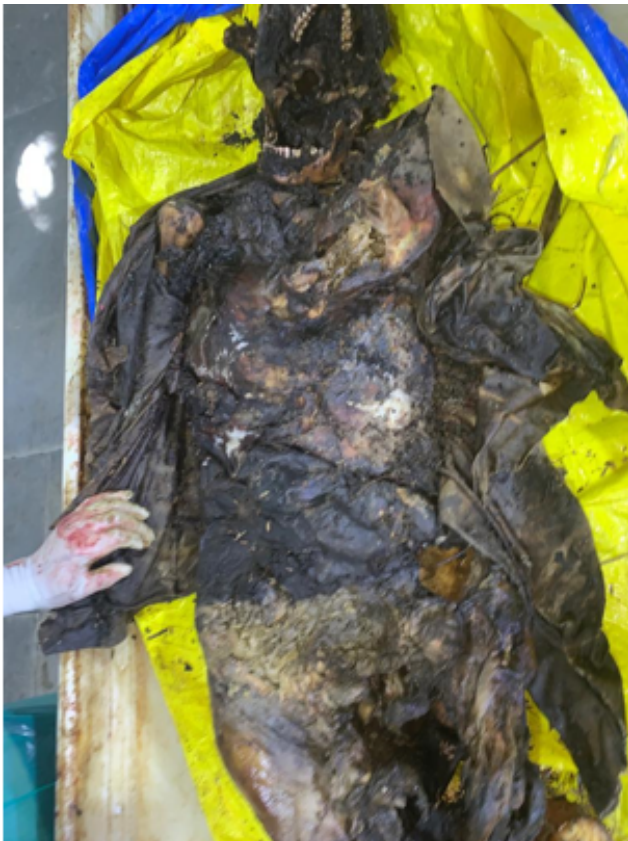

Figure 8: Dry, Leathery, shrivelled mummified tissue over the abdomen covered by thick jacket.



Figure 10: Larval and pupal forms of *dermestes maculatus*.



Figure 11: Irregular cut margins over lower 1/3rd of left tibia with absent left foot.



Figure 12: Irregular margins of lower 1/3rd of right forearm with absent right hand.

separation of mandible from the skull made it difficult to make out the features.

2. The appearance of *Dermestes maculatus* on decomposing remains of human and other animals makes it a candidate insect to estimate postmortem interval in cases of suicide, homicide, or unattended death. Adults generally arrive five to 11 days following death (Richardson and Goff 2001).⁴ This beetle can become one of the dominant insects present in mid to late decay. The hotter and drier the conditions the corpse is kept in limits fly larval development on the corpse, as they need softer material to eat. These conditions are more favourable to the hide beetles such as *Dermestes maculatus* (Schroeder et al. 2002).⁵
3. Larvae do not appear on corpses until the later stages of decay when the body has dried out. Full development of *Dermestes maculatus* is only reached when temperatures are consistently above 18°C, and will take 96 days at 18°C from the time the egg is laid to reach adulthood (Arnaldos et al. 2004). The optimum temperature for *Dermestes maculatus* development is approximately 30°C, where the beetles reach adulthood around 38 days (Richardson and Goff 2001). Even though there are adult forms and larval stages as well present over the body the temperature maintained during decay was unknown. Taking the last seen alive also into

consideration in this case the post-mortem interval is given as approximately 4 to 5 weeks prior to post-mortem examination.

4. No weapon was found near by the body but based on the histopathological report there are empty lacunar spaces, osteocytes and bone marrow nuclei are less in number significantly with absent hemosiderin deposits. The injuries over the lower end of left tibia and right forearm are ante-mortem in nature but exact time of injury is not known.
5. The opinion in this case as to the cause of death is given as due to Multiple injuries.

4. Discussion

Determination of individuality or identification is one of the prime issues in forensic practice. Some of the important parameters usually noted for the purpose of identification are race, gender, age, skin texture and features, speech and voice, footprints, deformities, hair, tattoo marks, scars, occupational marks, handwriting, garments and personal articles, gait pattern, and DNA profile. This may lead to either circumstantial identification or positive identification.⁶

1. In the case.1 even though we have parameters like tattoo mark, finger prints and DNA profile the exact identity of the individual is not known as there is no data base or any claimant available initially. Loss of gross identification features is the major drawback.
2. Post mortem changes depend on a diverse range of variables. Factors such as the ambient temperature, season, and geographical location at which the body is found, the fat content of the body, sepsis/injuries, intoxication, presence of clothes/insulation over the body, etc. determine the rate at which post-mortem changes occur in a cadaver. Understanding the post mortem changes is imperative to estimate the time since death (TSD) or the post mortem interval (PMI).⁶

In both the cases even though the insect structure and activity help to some extent, exact time of death cannot be specified as other factors like temperature, humidity, clothing, infections also have to be taken into consideration,

In case.2 circumstantial evidence of last seen alive was taken into consideration and time since death has been commented along with the help of insect activity. Upper half of the body is covered by a thick jacket providing warm and dry conditions required for mummification whereas lower half of the body is exposed to warm and moist conditions resulting in adipocere. The presence of differential decomposition changes in the same cadaver created some confusion.

- Both the bodies were found in isolated areas, the animal gnawing activity is undetermined due to advanced state of decay.
- Toxicological analysis was negative in the first case and viscera and muscle tissue were hardened in the second case making it difficult for analysis.
- Presence of thoracotomy tube in the first case gives the hint about infection in the body but the reason for the presence of body in the isolated area not known. The chance to correlate the injuries over the bones and over the soft tissue is lost in the second case.

5. Conclusion

In India time since death is mentioned almost in every post-mortem report done by forensic pathologist and this is given entirely based on naked eye changes after death. In court proceedings the Honourable judges relies heavily on Time since death given in the autopsy report to decide the culpability of the accused. This is a matter of concern as there are no studies in Indian scenario to substantiate or to refute the claims of international literature to the rate of decomposition changes in the cadaver.⁷ In order to have better understanding over the decomposition changes in different settings and climates, to gain scientific credibility regarding Time since death, cause of death and more other potential information 'Body farms' for taphnomical studies should be developed in India. The Total Body Score (TBS), Degree of Decomposition Index (DDI), Accumulated Decomposition Score (ADS), Total Aquatic Decomposition (TAD) and Accumulated Degree Days (ADD) which has been extensively used as predictor variables for PMI estimation. equations.⁸

6. Source of Funding

None.

7. Conflict of Interest

None.

References

- Byard RW, Tsokos M. The challenges presented by decomposition. *Forensic Sci Med Pathol*. 2013;9:135–137.
- Hall M, Whitaker A, Richards C. Forensic Ecology Handbook: From Crime Scene to Court, First Edition. *Natural History Museum*. 2012;.
- Agrawal V, Mehta HK, Shakya M, Jayraw AK, Jatav G. Application of Forensic Entomology to estimating Time Since Death. *J Anim Sci Livest Prod*. 2021;5(5).
- Richardson MS, Goff ML. Effects of temperature and intraspecific interaction on the development of *Dermestes maculatus* (Coleoptera: Dermestidae). *Journal of Medical Entomology*. 2001;38:347–351.
- Schroeder H, Klotzbach H, Oesterhelweg L, Püschel K. Larder beetles (Coleoptera: Dermestidae) as an accelerating factor for decomposition of a human corpse. *Forensic Science International*. 2002;127:231–236.
- Distribution of fingerprint patterns in an Indian population. *Malaysian Journal of Forensic Sciences*. 2014;5(2):18–20.
- Shedge R, Krishan K, Warriar V. Postmortem Changes. In: Stat Pearls. StatPearls Publishing; 2023.
- Arijit Dey¹, Hemant K. Kanwar², Varun Chandran³, Neha Sharma⁴. *Journal of forensic chemistry and Toxicology*. 2019;5(1).

Author biography

Kandhimalla Ambica, PG Student

Taqiuddin Khan, Professor & VicePrincipal

Cite this article: Ambica K, Khan T. Challenges presented by decomposition in medico-legal autopsies-A case series. *IP Int J Forensic Med Toxicol Sci* 2023;8(4):171-176.