

Content available at: <https://www.ipinnovative.com/open-access-journals>

IP International Journal of Forensic Medicine and Toxicological Sciences

Journal homepage: <http://www.ijfmts.com/>

Original Research Article

Antioxidant, Anti-inflammatory and hepatoprotective activities of *Persicaria maculosa* (linn.) and its active principle i.e tannic acid against Carbon tetrachloride induced oxidative stress and hepatotoxicity in wistar rats

Mohd. Shafi Dar^{1,*}, Deepak Kumar Mittal¹, Shazia Tabasum²¹Dept. of Zoology, Sri Satya Sai University of Technology and Medical Sciences, Sehore, Madhya Pradesh, India²Barkatullah University, Bhopal, Madhya Pradesh, India

ARTICLE INFO

Article history:

Received 07-03-2022

Accepted 11-03-2022

Available online 13-04-2022

Keywords:

Antioxidant
Anti-inflammatory
hepatoprotective
Hepatotoxicity
Histopathology
Persicaria maculosa
Silymarin
Tannic acid.

ABSTRACT

Background and Objective: *Persicaria maculosa* (linn.) contains antibacterial, anti-inflammatory, and antioxidant activities, although its protective effects in liver cells are debatable. The effect of *Persicaria maculosa* (PM) and its active principle, tannic acid (TA), aqueous extracts on carbon tetrachloride-induced hepatotoxicity in rats was investigated in this work.

Materials and Methods: Forty-two male Wistar rats were divided into seven groups: group-I act as Normal group, group-II (Toxicant group CCl₄ 1.5ml/kg i.p), group-III Standard group which pre-treated with silymarin (100mg/kg/day), groups-IV & V which were pretreated with PM aqueous extracts at a dosage of 200 & 400 mg/kg/day o.p, followed by CCl₄, groups-VI & VII which were pretreated with aqueous extracts of TA at doses of 200 & 400 mg/kg/day o.p followed by CCl₄ respectively. After 14 days, liver enzymes such as alanine aminotransferase (ALT), aspartate aminotransferase (AST), and alkaline phosphatase (ALP), bilirubin (BIL), and also oxidative stress biomarkers including lipid peroxidation (LPO), in vitro antioxidant activity were measured by 2,2'-diphenyl-1-picrylhydrazyl (DPPH). Quantitative determination of some vital phytochemicals, and the histopathological changes were determined using standard procedure.

Results: The findings showed that CCl₄ caused a remarkable rise in levels of serum hepatic enzymes such as ALT, AST, ALP and BIL (P≤0.001) compared with the control group. In addition, CCl₄ led to the increasing of LPO (P≤0.001) in liver tissue in comparison with the control group. Rats pretreated with silymarin significantly reduced the adverse effects of CCl₄ on serum and tissue markers. In this regard, remarkable vascular congestion, hepatocellular degeneration, and vacuolization were observed in hepatic tissue of CCl₄-treated rats. The pre-treatment of *Persicaria maculosa* and tannic acid aqueous extracts shows a significant improvement was observed in the functional and oxidative stress indices of hepatic tissue alongside histopathology changes.

Conclusion: The current investigation found that *Persicaria maculosa* and its active ingredient Tannic acid aqueous extracts may help to reduce hepatic oxidative injury in rats exposed to CCl₄ by enhancing the oxidant/antioxidant balance.

This is an Open Access (OA) journal, and articles are distributed under the terms of the [Creative Commons Attribution-NonCommercial-ShareAlike 4.0 License](https://creativecommons.org/licenses/by-nc-sa/4.0/), which allows others to remix, tweak, and build upon the work non-commercially, as long as appropriate credit is given and the new creations are licensed under the identical terms.

For reprints contact: reprint@ipinnovative.com

1. Introduction

The liver is one of the largest organs in the human body, and it controls metabolism, secretion, storage, and detoxification. Hepatic injury is frequently associated to

* Corresponding author.

E-mail address: darphdzology2020@gmail.com (M. S. Dar).

changes in these processes.¹ The majority of hepatotoxic substances harm liver cells by causing lipid peroxidation (LPO) or oxidative damage.²

The difference between free radical formation and antioxidant defence mechanisms is referred to as oxidative stress. As a result, free radicals assault biomolecules such as lipids, proteins, and DNA, resulting in a variety of disorders at the cellular and organ level, culminating in a disease aetiology such as hepatotoxicity, inflammation, cancer, diabetes, cardiovascular, and neurodegenerative disorders etc.^{3,4} DNA damage, lipid peroxidation, and protein oxidation are all caused by oxidative stress, but it also interferes with the physiologic adaption process and the control of intracellular signal transduction pathways.⁵ Antioxidants (enzymatic and non-enzymatic) found in living systems are usually effective at neutralising free radicals' negative effects. Synthetic antioxidants are being employed in a variety of food and pharmaceutical industries, despite the fact that they have been linked to toxicity. As a result of their superior efficacy and fewer negative side effects on health, consumers are increasingly seeking natural antioxidants.^{6–8}

Hepatotoxicity is a frequent condition that can have catastrophic implications ranging from metabolic problems to death.^{9,10} Different toxic materials can cause liver damage in this way. The chemical liver injury was assessed using a carbon tetrachloride (CCl₄)-induced liver injury model. CCl₄ is a powerful toxin that is commonly utilised in scientific study to provide experimental models that simulate oxidative stress in a variety of pathophysiological conditions.¹¹ The toxicity of CCl₄ is dependent on the formation of trichloromethyl radical (CCl₃•), which in the presence of oxygen is converted to trichloromethyl peroxy radical (CCl₃O₂•), which is more lethal than trichloromethyl radicals.¹² By interacting with lipids, proteins, and DNA, these radicals cause peroxidative degeneration in a variety of tissues. CCl₄ is the best model for the formation of reactive oxygen species (ROS) in numerous tissues, according to several prior research investigations.¹³ After CCl₄ injection, ROS such as superoxide anion, hydroxyl radical, hydrogen peroxide, and other radicals are produced, resulting in oxidative stress.^{14,15} ROS has also been shown to activate matrix metalloproteinase (e.g., collagenase), resulting in enhanced tissue degradation, as seen in various arthritic reactions.¹⁶ As a result, natural compounds that can reduce ROS could be beneficial in the treatment of inflammatory diseases.

Several research investigations on many herbal remedies have been undertaken to guard against CCl₄ poisoning by increasing antioxidant enzymes. Since ancient times, medicinal plants have played an important role in the treatment of various diseases. Plants and their bioactive substances have played a vital role in the treatment of many liver illnesses in the lack of focused hepatoprotective

medications in allopathic treatments. Plant extracts have continued to play an important role in human health care, particularly in poor nations, where more than 80% of the world's population uses phytomedicine as a source of health care.¹⁷ Due to the bioactive phytochemicals present, decades of research has shown significant improvement from using a variety of plant parts, either natively or as extracts, in the treatment of a variety of illnesses.^{18–20} Phytochemicals are plant-derived compounds that have the ability to alter human metabolism in ways that are advantageous to the prevention of chronic and degenerative diseases.^{21,22}

Silymarin is a polyphenolic flavonoid derived from *Silybum marianum*'s fruit and seed (milk thistle). It is a well-known hepatic damage therapeutic agent that has been utilised to treat liver cirrhosis and severe hepatitis. Silymarin is also helpful in reducing the effects of toxic substances.²³ Hepatic, renal, neuronal, and gastric damage have all been found to be protected by silymarin.²⁴ Silymarin's hepatoprotective activity is linked to its ability to stabilise cytoplasmic membranes.²⁵ Silymarin has been shown to have a significant therapeutic effect on hepatic damage of various etiologies in animal models.^{8,26}

Persicaria (smartweed) is a genus of almost 100 species in the Polygonaceae family.²⁷ The plants are either perennials or annuals.^{28,29} *Persicaria maculosa* Gray [syn. *Polygonum persicaria* L., (lady's thumb)] is a weed native to Europe that has spread over temperate and tropical North and South America, Asia, North Africa, and Australia as a weed.³⁰ The leaves and young shoots can be consumed in salads, and the plant has been used to treat diarrhoea and infectious infections.³¹ *Persicaria maculosa* has been used in the treatment of wounds and the prevention of fungal infections.³² *P. maculosa* boiled leaves have been employed in the making of pistio, a very old traditional Italian meal.^{33,34} This species contains stilbenes, flavonoids, phenolic acids, sesquiterpenes, and diterpenes, according to previous phytochemical research.^{28,35,36} In vitro pharmacological tests revealed that the plant has antibacterial, antifungal, and insecticidal properties.^{37,38} Persilben, a unique naturally occurring E-stilbene with antibacterial, antifungal, and antioxidant properties as well as strong penetration into biological membranes due to its high lipophilicity,^{39,40} has attracted attention as a chemical ingredient responsible for the observed actions. Furthermore, the plant's flavonoids contain anti-inflammatory and antioxidant properties.⁴¹

Tannic acid (TA) is a polyphenolic hydrophilic molecule found in green tea, fruits, cereals, red wine, and nearly all plants.^{42,43} TA is a water-soluble polyphenol molecule with a complicated chemical structure (C₇₆H₅₂O₄₆; Fig. 1), with a glucose core covalently connected to 3-5 gallic acid residues via ester bond hydrolysis.⁴⁴ In vivo research on animals and humans have shown that the

bioavailability of polyphenols like TA varies greatly, with the experimental setup and the chemical structure of the polyphenolic compounds playing a role. According to Afsana et al.,⁴⁵ around 85% of digested TA vanished from the colon in rats, implying that the majority of ingested TA was hydrolyzed in the large intestine and absorbed as gallic acid or degraded further. Numerous studies show that TA possesses anti-oxidant,⁴⁶ anti-inflammatory,⁴⁷ anti-apoptotic,⁴⁸ and anti-carcinogenic properties.⁴⁹ Our earlier research has demonstrated that TA can protect against not only acetaminophen-induced hepatotoxicity,⁵⁰ but also acute doxorubicin-induced cardio-toxicity by reducing inflammation, oxidative stress, and apoptosis.⁵¹ TA has also been shown to inhibit lipid oxidation by scavenging radicals.^{52,53} Antioxidant, anti-inflammatory, anticarcinogenic, antimutagenic, and anti-atherogenic activities of TA have been discovered.⁵⁴ It also has the ability to defend against medication toxicity.⁵⁵

However, no studies have been done on the medicinal potential of *Persicaria maculosa* and its active ingredient, tannic acid, in aqueous extracts as a hepatoprotectant against CCl₄-induced toxicity. The antioxidant and hepatoprotective properties of *Persicaria maculosa* aqueous extracts and its active principle, tannic acid, against CCl₄-induced oxidative stress and hepatotoxicity are reported in this study. To our knowledge, this is the first study to examine the antioxidant and hepatoprotective properties of *Persicaria maculosa* aqueous extracts and their active principle, tannic acid, against CCl₄-induced liver injury in albino Wistar rats.

2. Materials and Methods

2.1. Collection of plant, identification and extraction

Persicaria maculosa were collected from Lethpora, Pampora, Kashmir near the river Jhelum in July 2018 and identification was confirmed by Prof. Akhtar H. Malik (Centre for Biodiversity and Taxonomy, Department of Botany, University of Kashmir) With voucher specimen Herbarium No. 2925 (KASH). The root parts of *Persicaria maculosa* were shade dried at room temperature for 10–15 days, ground into a fine powder and extracted sequentially with water using the maceration method and then filtered with No. 1 Whatman filter paper. The pure filtrate was then concentrated to dryness in an oven at 40°C.

2.2. Phytochemical chemicals

The secondary metabolites such as alkaloids, saponins, tannins, flavonoids, steroids, terpenoids, proteins, amino acids, glycosides, and anthraquinones were identified using standard methods on the *Persicaria maculosa* extract.^{56,57}

2.3. Chemicals

Standard sources were used to get silymarin (Sigma), tannic acid (Himedia laboratories Pvt Ltd.), and CCl₄ (Sisco Research Laboratory Pvt Ltd.). Erba Transasia Biomedicals Ltd provided biochemical kits for the measurements of alkaline phosphatase (ALP), serum glutamic-oxaloacetic transaminase (SGOT), serum glutamic pyruvic transaminase (SGPT), and bilirubin (BIL). All other laboratory chemicals were acquired from Sisco research laboratory Pvt. Ltd. in New Delhi, India, including 2,2'-diphenyl-1-picrylhydrazyl (DPMH), tris HCl buffer, butanol, pyridine, TBA, hydrogen peroxide, and some others.

2.4. Antioxidant activity

The DPMH 1, 1-diphenyl-2-picrylhydrazyl (DPMH) Assay was used to determine the extract's free radical scavenging capacity.⁵⁸ The scavenging activity of the stable 1, 1-diphenyl-2-picrylhydrazyl (DPMH) Free radical was used to determine the antioxidant properties of *Persicaria maculosa* extracts and tannic acid. Different concentrations (20-100 g) of a 0.1Mm DPMH solution in methanol (0.2ml). The mixture was vortexed and left for 30 minutes in a dark room at room temperature. For the baseline correction, a DPMH blank was made without chemical and methanol was utilized. The reference standard was ascorbic acid. Using a UV-Visible spectrophotometer, the decrease in absorbance at 517nm was measured, and the residual DPMH was determined. The radical scavenging activity was expressed as the percentage inhibition and was calculated using the following formula: Percentage of Inhibition = $[(A_0 - A_1)/A_0] \times 100$. Where A₀ is the absorbance of the control (without compound) and A₁ is the absorbance of the compound. The IC₅₀ (concentration causing 50% inhibition) values of each compound was determined graphically.

2.5. Acute toxicity test

The OECD test guidelines for acute oral toxicity test OECD-423 were used to conduct the acute oral toxicity research, which followed the standard method protocol.⁵⁹ Five groups of six rats were formed. The first was used as a standard control group. Oral doses of *Persicaria maculosa* and tannic acid of 5, 50, 300, and 2000 mg/kg b.w.p.o. were given to separate groups. The rats in the experiment were allowed free access to meals and drinks and were monitored for 14 days for any signs of mortality or behavioural changes.

2.6. Experimental animals

Wistar male albino rats (weight 130±10 g) were used in the experiments. They were maintained in a temperature (24 ±

2°C) and humidity (40% ± 5%) controlled environment with a 12 h light/dark cycle. Rats were provided with a standard rodent diet and water ad libitum. The study was carried out according to the Guidelines of Institutional Animal Ethics Committee, at Pinnacle Biomedical Research Institute (PBRI) Bhopal, Madhya Pradesh, India in agreement with the Committee for the Purpose of Control and Supervision of Experiments on Animals.

2.7. Experimental design

After one week of acclimatization, the animals were divided randomly into seven groups each having six animals and treated as follows: Group I was normal control and received normal saline only. Group II was toxic, given dose of CCl₄ 1.5 ml/kg i.p (1:1 v/v) solution in olive oil. Group III received pretreatment with Silymarin (100 mg/kg) orally for 14 days and, on the last day, was given CCl₄. Group IV & V pretreated with *Persicaria maculosa* at doses of (200 & 400 mg/kg) orally for 14 days and, on the last day, was given CCl₄. Group VI & VII pretreated with tannic acid at doses of (200 & 400 mg/kg) orally for 14 days and, on the last day, was given CCl₄.

The animals were anaesthetized with ethyl ether on the 16th day, and blood was extracted via retro-orbital puncture, blood samples were obtained, serum was isolated from blood, and an Erba Diagnostic Kit was used to perform a marker of liver function test. The serum samples were stored at -20°C after centrifugation at 3000 rpm for 10 minutes. For biochemical investigation, a piece of fresh liver was removed and kept at -80°C. For histological investigation, a piece of rat liver was removed and placed in 10% formalin.

2.8. Biochemical analysis

2.8.1. Assessment of liver marker enzymes in serum

The biochemical parameters viz., SGPT, SGOT, ALP, and bilirubin were assayed using commercially available kits (Erba Diagnostics Kits).

2.8.2. Preparation of hepatic tissue homogenate

Hepatic tissue (100 mg) was homogenised in 1 mL phosphate buffered saline (50 mM, pH 7.3) and centrifuged at 3000 rpm for 10 minutes at 4°C. For biochemical investigation, the supernatant was isolated.⁶⁰

2.8.3. Measurement of lipid peroxidation

The bioactive aldehydes produced by hepatic lipid peroxidation (LPO) were measured using the thiobarbituric acid reactive substances (TBARS) method.⁶¹ In a brief, 100µl of liver tissue homogenate were combined with 500µl of reagent containing 0.2% thiobarbituric acid (TBA) in H₂SO₄ (0.05 M). In a boiling water bath, the mixture was boiled for 30 minutes at 100°C. Then, using varying amounts of malondialdehyde (MDA) as a standard, the

optimal absorbance was determined at 532 nm, and the results were reported as nmol/mg protein.

2.8.4. Histological analysis of liver

The rats' liver samples were fixed in 10% formalin, then dehydrated in graded alcohol before being embedded in paraffin wax. Using an SPINCON rotary microtome, the paraffin-embedded tissue was serially sectioned (5 µm). The sections were stretched and stained with hematoxylin and eosin (H&E) dyes after being placed on albumin-coated sterile glass slides.⁶² After being mounted with dibutylphthalate polystyrene xylene (DPX), the slides containing tissue sections stained with H&E were examined under a light microscope at ×10 magnification.

2.8.5. Statistical analysis

All data was expressed as mean ± standard deviation (n = 6 in each group). The significance of the biochemical results of the different groups was tested using a one-way ANOVA. The significance level is set to p ≤ 0.001.

3. Results

3.1. Phytochemical analysis

Using phytochemical screening, we discovered that the aqueous extract of *Persicaria maculosa* contains phenols, flavonoids, saponins, glycosides, steroids, tannins, terpenoids, and amino acids (Table 1).

Table 1: Preliminary phytochemical screening of *Persicaria maculosa* aqueous extract.

Phytochemical constituents	Aqueous extract
Flavonoids	+
Phenols	+
Alkaloids	+
Proteins	+
Terpenoids	+
Steroids	+
Saponins	+
Glycosides	+
Anthraquinones	+
Amino acids	+
Tannins	+

Positive (+), and Negative (-).

3.2. DPPH radical scavenging activity

The ability of *Persicaria maculosa* and tannic acid to scavenge DPPH radicals was used to measure their antioxidant activity. With an IC₅₀ of 54.48 µg ml⁻¹ and IC₅₀ = 49.41 µg ml⁻¹, *Persicaria maculosa* and tannic acid showed DPPH radical scavenging activity, which was equivalent to that of ascorbic acid (IC₅₀ 37.62 µg/ml⁻¹). Table 2.

Table 2: DPPH scavenging activities of extract of *Persicaria maculosa* and its active principle i.e Tannic acid.

Concentrations $\mu\text{g ml}^{-1}$	% inhibition		
	<i>Persicaria maculosa</i>	Tannic acid	Ascorbic acid (Standard)
20 $\mu\text{g ml}^{-1}$	29.34	30.00	40.58
40 $\mu\text{g ml}^{-1}$	41.41	45.71	50.58
60 $\mu\text{g ml}^{-1}$	51.57	57.61	62.98
80 $\mu\text{g ml}^{-1}$	68.85	70.66	71.74
100 $\mu\text{g ml}^{-1}$	75.29	78.02	79.59
IC ₅₀ =	IC ₅₀ = 54.48 $\mu\text{g ml}^{-1}$	IC ₅₀ = 49.41 $\mu\text{g ml}^{-1}$	IC ₅₀ = 37.62 $\mu\text{g ml}^{-1}$

Values were expressed as mean \pm SD for triplicates

3.3. Acute toxicity studies

No mortality was observed in rats given up to 2000 mg/kg of *Persicaria maculosa* and tannic acid orally. In addition, treated rats showed no significant behavioural changes or food aversion. Table 3

Table 3: Acute toxicity of aqueous extract of *Persicaria maculosa* & its active principle i.e Tannic acid.

Oral Doses (mg kg^{-1} b.wt)	Mortality	
	<i>Persicaria maculosa</i>	Tannic acid
5 mg kg^{-1}	Nil	Nil
50 mg kg^{-1}	Nil	Nil
300 mg kg^{-1}	Nil	Nil
2000 mg kg^{-1}	Nil	Nil

3.4. *Persicaria maculosa* and its active ingredient, tannic acid, have an inhibitory effect on CCl₄-induced hepatotoxicity.

ummarises the findings of the hepatoprotective effect of *Persicaria maculosa* and Tannic acid. AST, ALT, ALP, and TB levels all increased significantly in the CCl₄ group. However, when *Persicaria maculosa* and Tannic acid were used to pre-treat the plants, this rise was significantly reduced. These findings suggested that PM and TA could protect the liver from CCl₄-induced damage. Group III rats administered with the standard medication silymarin demonstrated considerable ($p \leq 0.001$) protection against CCl₄-induced liver damage.

Values are expressed as mean \pm SD; n=6. Aqueous extract from PM (*Persicaria maculosa*), TA (Tannic acid); AST (aspartate aminotransferase); ALT (alanine aminotransferase); ALP (alkaline phosphatase); BIL (bilirubin); MDA (malondialdehyde).

3.5. Effect of *Persicaria maculosa* and tannic acid on MDA level in liver

Hepatic lipid peroxidation was measured using the MDA level. Table 4 shows the effects of *Persicaria maculosa* and Tannic acid on CCl₄-induced lipid peroxidation. MDA levels were substantially higher in the CCl₄ group ($p \leq 0.001$). On the other hand, Pre-treatments with PM & TA and silymarin, lowered MDA levels.

3.6. Histopathological studies

Normal rat liver slices showed a normal lobular architecture with a central vein and radiating hepatic cords, as well as intact hepatocytes with sinusoidal gaps and evenly distributed cytoplasm in histological sections (Figure 1A). The CCl₄-treated group showed morphological changes and fibrosis, as evidenced by disruption of tissue architecture, fibre extension, massive fibrous septa development, pseudo-lobe separation, and fibre accumulation. Massive hepatocellular degeneration, necrosis, sinusoidal dilatation, inflammatory cell infiltration, and cytoplasmic vacuolation are all signs of this (Figure 1B). In silymarin-treated rats, the changes were almost reversed, with portions of normal liver architecture and patches of necrotic hepatocytes (Fig. 2C). When compared to Group II, the liver sections of rats pre-treated with PM (200 mg/kg Figure 1D & 400 mg/kg Figure 1E) followed by CCl₄ showed a relatively normal lobular pattern with a minor degree of fatty alteration, necrosis, and lymphocyte infiltration (CCl₄ control). However, when compared to Group II (CCl₄ control), pre-treatments of TA extracts (200 mg/kg, Figure 1F & 400 mg/kg, Figure 1G) followed by CCl₄ resulted in a reasonable improvement in hepatic architecture as measured by reduced liver damage and associated hepatic injuries by suppressing hepatocellular degeneration and necrosis and thus significantly improving liver structure and function.

4. Discussion

The liver is responsible for the metabolism, synthesis, storage, and redistribution of nutrients, carbohydrates, lipids, and vitamins, and hence plays a key role in metabolic homeostasis. It is also the body's major detoxification organ, removing wastes and xenobiotics by metabolic conversion and biliary excretion.⁶³

Drugs, toxins, and excessive alcohol intake can all cause liver damage. There is an urgent need for the development of powerful and nontoxic hepatoprotective medicines for the treatment of liver damage due to a dearth of reliable hepatoprotective therapies in modern medicine.⁶⁴ Medicinal herbs have long been utilised in traditional medicine to treat liver problems in many regions of the world, particularly in developing countries. These plants have been suggested for in vivo pharmacological

Table 4: Effect of aqueous extract from *Persicaria maculosa* & Tannic acid on biochemical parameters & hepatic antioxidant enzymes activity in liver homogenate in damaged liver rats induced by CCl₄.

Design of treatment	AST (U/L)	ALT(U/L)	ALP (U/L)	BIL (mg/dl)	MDA (nmol/mg protein)
Group I normal control	135.69±11.761	49.05 ± 7.821	117.18 ± 7.494	0.41 ± 0.067	23.94 ± 2.707
Group II CCl ₄ control (1.5 ml/kg, i.p.)	168.8 ± 12.95	76.90 ± 4.449	222.11 ± 27.16	2.00 ± 0.062	78.08 ± 0.880
Group III SLY (100 mg/kg + CCl ₄)	132.16 ± 19.97	47.73 ± 8.294	113.22 ± 5.905	0.46 ± 0.056	33.92 ± 2.492
Group IV PM (200 mg/kg + CCl ₄)	157.35 ± 9.242	64.97 ± 6.827	163.94 ± 9.248	1.085 ± 0.042	62.44 ± 1.566
Group V PM (400 mg/kg + CCl ₄)	150.3 ± 9.467	58.34 ± 5.589	145.16 ± 7.304	0.65 ± 0.075	55.08 ± 2.538
Group VI TA (200 mg/kg + CCl ₄)	143.09 ± 5.695	57.46 ± 6.038	151.33 ± 6.800	0.88 ± 0.104	59.83 ± 2.116
Group VII TA (400 mg/kg + CCl ₄)	139.2 ± 9.399	53.03 ± 6.921	130.92 ± 8.153	0.53 ± 0.057	42.06 ± 2.656

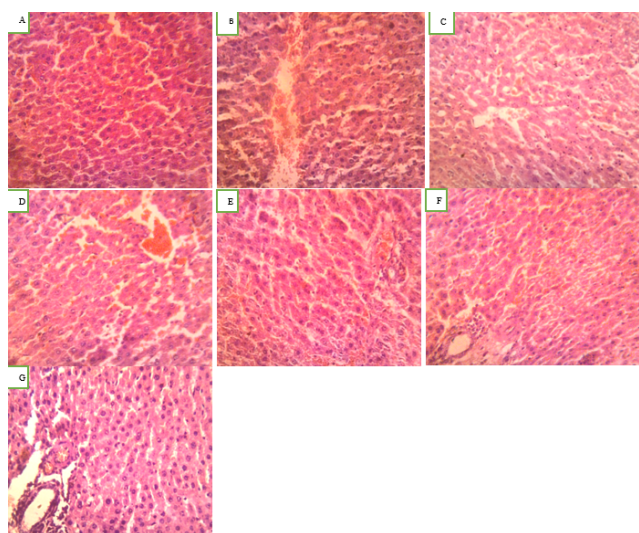


Fig. 1: Histopathological analysis of experimental liver tissues following administration of *Persicaria maculosa* and Tannic acid aqueous extracts against CCl₄ treated rats; **A:** Control rats; **B:** CCl₄ (1.5 ml kg⁻¹i.p) treated rats; **C:** silymarin (100 mg kg⁻¹) + CCl₄ (1.5 ml kg⁻¹i.p) treated rats; **D:** PM (200 mg kg⁻¹) + CCl₄ (1.5 ml kg⁻¹i.p) treated rats; **E:** PM (400 mg kg⁻¹) + CCl₄ (1.5 ml kg⁻¹i.p) treated rats; **F:** TA (200 mg kg⁻¹) + CCl₄ (1.5 ml kg⁻¹i.p) treated rats; **G:** TA (400 mg kg⁻¹) + CCl₄ (1.5 ml kg⁻¹i.p) treated rats. The blue color arrow represents central vein; black arrow represents the nucleus, and the yellow arrow represents inflammatory cells.

testing in order to identify good candidates.⁶⁵ Furthermore, medicinal herbs with anti-inflammatory and antioxidant properties have emerged as promising options for research into tissue repair.⁶⁶

The negative effects of medicines and synthetic antioxidants have prompted researchers to look for new natural antioxidants and hepatoprotectants that are more effective at controlling oxidative stress and preventing

disease progression.^{67,68} Antioxidants are chemicals that hinder the propagation of oxidative chain reactions, hence inhibiting the oxidation of essential biomolecules.⁶⁹ However, this is the first study to look at the antioxidant, anti-inflammatory, and hepatoprotective properties of PM and TA aqueous extracts in albino wistar rats who were exposed to CCl₄.

The presence of alkaloids, saponins, tannins, flavonoids, steroids, terpenoids, proteins, amino acids, glycosides, and anthraquinones was discovered using phytochemical screening in this study (Table 1). These phytochemicals are said to have therapeutic and health-promoting qualities.^{70,71} The most abundant was phenol, which has antioxidant and hepatocurative characteristics.⁷² Flavonoid was also prevalent, which could explain its potent antioxidant capabilities.⁷³ The extract also contains a significant amount of tannin and alkaloid, both of which have antioxidant qualities.⁷⁴ The phytochemical components contained in any extract contribute to the total antioxidative capacity of the extract, and a higher phenolic concentration causes the plant material to operate as an antioxidative agent.⁷⁵

The antioxidant activity of PM and TA was studied in this work by evaluating their involvement in DPPH radical scavenging activity. DPPH is a molecule that contains a persistent free radical that, when given an electron by antioxidants, reduces the intensity of its purple solution and, as a result, its absorbance.⁷⁶ The antioxidant activity of the aqueous extract of *Persicaria maculosa* & tannic acid using DPPH method showed increased antioxidant activity as concentration increases. DPPH results PM & TA are in (Table 2) showed appreciable antioxidant activity (IC₅₀ = 54.48 μg ml⁻¹ and IC₅₀ = 49.41 μg ml⁻¹) compared with ascorbic acid (IC₅₀ = 37.62 μg ml⁻¹). The antioxidant activity of PM and TA against DPPH radicals in this assay can be attributed to a direct function in trapping free radicals by donating hydrogen atoms or electrons.

Although hydrogen peroxide is not particularly reactive, it can produce hydroxyl radicals, which can cause significant cell damage.⁷⁷ As a result, it's critical to find compounds that can effectively scavenge these reactive oxygen species. The DPPH technique revealed that PM and TA had mild to moderate antioxidant activity.

The toxicity of the extracts and pure components was assessed in albino wistar rats using the general guidelines of the Organisation for Economic Co-operation and Development (OECD) Guidelines for Chemical Testing.⁷⁸ According to the findings of this investigation, the acute toxicity analysis (LD₅₀) of the aqueous extract of *Persicaria maculosa* was larger than 2000mg/kg, indicating that the extract was relatively safe.

Hepatotoxicity was generated in this investigation by giving CCl₄ (1.5 ml/kg body weight), and the liver function indices of hepatic damage were raised, as shown in Table 4. The results showed that the rats in group II had higher levels of ALP, AST, ALT, BIL, and MDA (CCl₄ only). Pre-treatments with PM and TA at doses of 200 and 400 mg/kg considerably reduced these enzyme levels in a dose-dependent manner, similar to the effect of the conventional hepatoprotective medication silymarin. According to our findings, PM & TA were able to bring this level back to normal. As a result of its protective effect on membrane fragility, normal serum hepatic enzyme levels imply that PM & TA promotes in the regeneration of hepatoparenchymal cells. Our findings are consistent with earlier research.^{79,80}

CCl₄ poisoning has been shown to be a substantial source of free radical generation in a variety of organs, including the liver, kidney, lungs, brain, and blood.⁸¹ CCl₄ is commonly used to generate liver toxicity in vitro and in vivo models, and then plant-based medicines are tested for their liver-protective properties. In the liver, CCl₄ is actively converted to the extremely reactive trichloromethyl free radical CCl₃*. In the presence of molecular oxygen, CCl₃* interacts with cellular macromolecular protein and polyunsaturated fatty acids to create highly hazardous trichloromethyl peroxy radicals CCl₃O, H₂O₂, O₂⁻, OH, which cause liver damage.^{82–84} The CCl₄ induced liver damage raises liver marker enzymes and releases them into the bloodstream. Elevated serum enzyme levels, such as ALT and AST, indicate cellular leakage and loss of cell membrane functional integrity in the liver.^{84,85} the serum levels of ALT and AST were reduced to normal levels after treatment with PM and TA, indicating that the plasma membrane had stabilised and that the CCl₄-induced hepatic tissue damage had been repaired. ALP, on the other hand, is a marker for pathological changes in biliary flow.^{84,86} The increase in serum ALP caused by CCl₄ corresponds to high levels of serum bilirubin. The effective management of ALP and bilirubin levels in the PM and TA therapy groups indicates an early improvement in the hepatocyte secretory system.^{84,87} Intoxication

with CCl₄ promotes the disassociation and disruption of polyribosomes on the endoplasmic reticulum, decreasing protein production. By preserving the polyribosomes, the PM & TA therapy restored protein production. Histopathological investigations confirmed the chemical results.

LPO is a well-known oxidative stress and cell damage mechanistic pathway.⁸⁸ By producing unneeded free radicals and degrading macromolecules, CCl₄ increases oxidative stress. Our data suggest that intraperitoneal CCl₄ injection raises MDA levels, a key LPO indicator, which is comparable with Najmi et al., findings.⁸⁹ MDA is produced through the oxidation of polyunsaturated fatty acids. Furthermore, peroxidation hinders the body's natural antioxidant system by producing too many reactive free radicals.⁹⁰ The results of this study show that pretreatment with PM & TA reduces MDA levels in hepatic tissues (p<0.001) when compared to the CCl₄ group, indicating that the aqueous extract can protect against oxidative stress. This hepatoprotective action could be due to the existence of bioactive chemicals in PM & TA that have significant radical scavenging activity, which could explain the plant's traditional depurative function against hepatocellular injury.

Toxicity caused by CCl₄ treatment, as well as its alleviation by PM and TA extracts, was visible in histological sections of liver slices. Toxicity causes structural changes in hepatic tissue, and the degree of toxicity strongly correlates with the severity of liver injury.⁹¹ The histopathological examination of CCl₄-treated rat liver slices revealed ballooning, hepatocyte degeneration, hepatocellular necrosis, and inflammatory cell infiltration which were consistent with the assay results for biochemical parameters associated with hepatotoxicity in the serum and tissue. Further treatment with SLY, PM, and TA extracts improved morphological characteristics. As a result, alterations in histological sections corroborated the biochemical findings. The antioxidant effects of PM & TA in vitro and in vivo could be attributed to the flavonoids and phenolic chemicals included in the extract, which have been reported to have antioxidant and hepatoprotective properties.⁹² However, more research into the active chemicals and biochemical pathways underlying *Persicaria maculosa* & tannic acid's antioxidant and hepatoprotective properties is required.

According to the findings, *Persicaria maculosa* aqueous extract and tannic acid have strong preventive potential against oxidative stress and liver injury caused by CCl₄ ingestion. The study went on to say that plants and their chemicals have a lot of potential for reducing hepatotoxicity and oxidative stress caused by medication side effects.

5. Conclusion

In vitro and in vivo studies have demonstrated that aqueous extracts of *Persicaria maculosa* and one of its

bioactive components, tannic acid, and exhibit antioxidant and hepatoprotective properties. Intake of CCl₄, an anti-inflammatory drug, was found to cause hepatotoxicity in rats, as evidenced by changes in oxidative stress and liver function indicators in blood and tissue, as well as changes in liver sections. *Persicaria maculosa* & tannic acid aqueous extracts showed significant hepatoprotective activity in rats against oxidative stress and liver injury. PM & TA have hepatoprotective effectiveness comparable to silymarin. *Persicaria maculosa* components, according to the study, have tremendous therapeutic value as antioxidants, anti-inflammatory, and hepatoprotective agents. To our knowledge, this is the first study to indicate that *Persicaria maculosa* and tannic acid aqueous extracts can protect against carbon tetrachloride-induced hepatotoxicity. However, more research is needed to determine the specific mechanism of action of the numerous elements found in *Persicaria maculosa*, which could aid in the development of a novel natural medicinal drug.

6. Declaration of Competing Interest

The authors declared no potential conflicts of interest with respect to the research, authorship, and/or publication of this article.

7. Acknowledgments

The authors would like to thank Dr. Megha Jha Sr. Scientific Manager (R&D) Pinnacle Biomedical (PBRI) Bhopal, Madhya Pradesh India for her assistance & provided necessary research facilities to carry out the research work.

8. Conflict of Interest

The authors declare that there is no conflict of interest.

9. Source of Funding

None.

References

1. Wolf PL. Biochemical diagnosis of liver disease. *Indian J Clin Biochem.* 1999;14(1):59–90. doi:10.1007/BF02869152.
2. Dianzani MU, Muzio G, Biocca ME, Canuto RA. Lipid peroxidation in fatty liver induced by caffeine in rats. *Int J Tissue React.* 1991;13(2):79–85.
3. Sharma UK, Kumar R, Gupta A, Ganguly R, Pandey AK. Renoprotective effect of cinnamaldehyde in food color induced toxicity. *Biotech.* 2018;8(4):212. doi:10.1007/s13205-018-1241-z.
4. Kumar S, Gupta A, Pandey AK. Calotropis procera Root Extract Has the Capability to Combat Free Radical Mediated Damage. *ISRN Pharmacol.* 2013;p. 691372. doi:10.1155/2013/691372.
5. Sharma UK, Kumar R, Gupta A, Ganguly R, Singh AK, Ojha AK, et al. Ameliorating efficacy of eugenol against metanil yellow induced toxicity in albino Wistar rats. *Food Chem Toxicol.* 2019;126:34–40. doi:10.1016/j.fct.2019.01.032.
6. Sharma UK, Sharma AK, Gupta A, Kumar R, Pandey A, Pandey AK, et al. Pharmacological activities of cinnamaldehyde and eugenol: antioxidant, cytotoxic and anti-leishmanial studies. *Cell Mol Biol (Noisy-legrand).* 2017;63(6):73–8. doi:10.14715/cmb/2017.63.6.15.
7. Kumar R, Gupta A, Singh AK, Bishayee A, Pandey AK. The Antioxidant and Antihyperglycemic Activities of Bottlebrush Plant (*Callistemon lanceolatus*) Stem Extracts. *Medicines (Basel).* 2020;7(3):11. doi:10.3390/medicines7030011.
8. Gupta A, Pandey A. Aceclofenac-induced hepatotoxicity: An ameliorative effect of *Terminalia bellirica* fruit and ellagic acid. *World J Hepatol.* 2020;12(11):949–64.
9. Taju G, Jayanthi M, Majeed AS. Evaluation of Hepatoprotective and Antioxidant activity of *Psidium Guajava* Leaf Extract against Acetaminophen Induced Liver Injury in Rats. *Toxicol APMI Pharmacol.* 2011; Available from: <https://www.semanticscholar.org/paper/Evaluation-of-Hepatoprotective-and-Antioxidant-of-Taju-Jayanthi/e4d2b9475cd9284fa28e117c8abd44e066b38509>.
10. Mondal M, Hossain MM, Hasan MR, Islam MT, Tarun, Islam MAF, et al. Hepatoprotective and Antioxidant Capacity of *Mallotus repandus* Ethyl Acetate Stem Extract against d-Galactosamine-Induced Hepatotoxicity in Rats. *ACS Omega.* 2020;5(12):6523–31.
11. Yoshioka H, Usuda H, Fukuishi N, Nonogaki T, Onosaka S. “Carbon tetrachloride-induced nephrotoxicity in mice is prevented by pretreatment with zinc sulfate. *Biol Pharm Bull.* 2016;39(6):1042–6. doi:10.1248/bpb.b16-00078.
12. Ali SEM, Abdelaziz DHA. The protective effect of date seeds on nephrotoxicity induced by carbon tetrachloride in rats. *Int J Pharm Sci Rev Res.* 2014;26(2):62–8.
13. Kamisan FH, Yahya F, Mamat SS. Effect of methanol extract of *Dicranopteris linearis* against carbon tetrachloride induced acute liver injury in rats. *BMC Complement Alternat Med.* 2014;14:123. doi:10.1186/1472-6882-14-123.
14. Ritter C, Reinke A, Andrades M. Protective effect of N-acetylcysteine and deferoxamine on carbon tetrachloride-induced acute hepatic failure in rats. *Crit Care Med.* 2004;32(10):2079–83. doi:10.1097/01.ccm.0000142699.54266.d9.
15. Safhi MM. Nephroprotective Effect of Zingerone against CCl₄-Induced Renal Toxicity in Swiss Albino Mice: Molecular Mechanism. *Oxidative Med Cellr Longev.* 2018;7:1–7. doi:10.1155/2018/2474831.
16. Cotran RS, Kumar V, Robbins L. Robbins, Pathologic Basis of Disease. vol. 12. Philadelphia: W.B. Saunders Company; 1994. p. 377.
17. World Health Organization. Research Guidelines for Evaluating the Safety and Efficacy of Herbal Medicines. Manila, PhilipMines: World Health Organization Regional Office for Western Pacific; 1993. <http://apms.who.int/medicinedocs/en/d/Jh2946el>. Accessed August 2018; 31.
18. Gupta SS. Prospects and prospective of natural plant products in medicine. *Indian J Pharmacol.* 1994;26(1):1–12.
19. Michel A. Tree, Shrub and Liana of West African Zones. Paris, France: Margaf; 2002. p. 25.
20. Wang R, Kay J, Wang D, Lien LL, Lien EJ. A survey of Chinese herbal ingredients with liver protection activities. *Clin Med.* 2007;2:5. doi:10.1186/1749-8546-2-5.
21. Tripoli E, Guardia ML, Giammanco S, Majo DD, Giammanco M. Citrus flavonoids: molecular structure, biological activity and nutritional properties: a review. *Food Chem.* 2007;104(2):466–79. doi:10.1016/j.foodchem.2006.11.054.
22. Ihegboro GO, Ononamadu CJ, Afor E, Odogiyen GD. Cytotoxic and Hepatocurative Effect of Aqueous Fraction of *Tapinanthus bangwensis* Against Paracetamol-Induced Hepatotoxicity. *J Evid-Based Integ Med.* 2018;23. doi:10.1177/2515690X18801577.
23. Shalan MG, Mostafa MS, Hassouna MM, El-Nabi SE, El-Refaie A. Amelioration of lead toxicity on rat liver with Vitamin C and silymarin suPMlements. *Toxicology.* 2005;206(1):1–15. doi:10.1016/j.tox.2004.07.006.
24. Wang L, Huang QH, Li YX, Huang YF, Xie JH, Xu LQ, et al. Protective effects of silymarin on triptolide-induced acute hepatotoxicity in rats. *Mol Med Rep.* 2018;17(1):789–800. doi:10.3892/mmr.2017.7958.
25. Baradaran A, Samadi F, Ramezanpour SS, Yousefdoost S. Hepatoprotective effects of silymarin on CCl₄ - induced hepatic damage in broiler chickens model. *Toxicol Rep.* 2019;6:788–94.

- doi:10.1016/j.toxrep.2019.07.011.
26. Gillessen A, Schmidt HH. Silymarin as SuPMortive Treatment in Liver Diseases: A Narrative Review. *Adv Ther.* 2020;37(4):1279–301. doi:10.1007/s12325-020-01251-y.
 27. Available from: http://www.efloras.org/florataxon.aspx?flora_id=1&taxon_id=124629.
 28. Derita M, Zacchino S. Chemotaxonomic importance of sesquiterpenes and flavonoids in five Argentinian species of Polygonum genus. *J Essent Oil Res.* 2011;23(5):11–4. doi:10.1080/10412905.2011.9700474.
 29. Derita MG, Gattuso SJ, Zacchino SA. Occurrence of polygodial in species of Polygonum genus belonging to Persicaria section. *Biochem Syst Ecol.* 2008;36:55–8. doi:10.1016/j.bse.2007.05.011.
 30. Available from: <http://www.efloras.org/florataxon.aspx>.
 31. Available from: <https://bie.ala.org.au/species/http://id.biodiversity.org.au/node/apni/2894047>.
 32. Derita M, Zacchino S. Validation of the ethnopharmacological use of Persicaria maculosa for its antifungal properties. *Nat Prod Commun.* 2011;6(7):931–3.
 33. Paoletti MG, Dreon A, Lorenzoni G. *Econ Bot.* 1995;49(1):26–30.
 34. Jovanović M, Morić I, Nikolić B, Pavić A, Svirčev E, Šenerović L, et al. Aleksandar Pavić, Emilija Svirčev, Lidija Šenerović and Dragana Mitić-Culafi; Anti-Virulence Potential and In Vivo Toxicity of Persicaria maculosa and Bistorta officinalis Extracts. *Molecules.* 2020;25(8):1811. doi:10.3390/molecules25081811.
 35. Smolarz HD. Chromatographical analysis of phenolic acids in some species of Polygonum L genus. Part 2 - Quantitative determination of the major components by high performance liquid chromatography (HPLC). *Acta Soc Bot Pol.* 2000;69(1):21–3.
 36. Protá N, Mumma R, Bouwmeester HJ, Jongsma MA. Comparison of the chemical composition of three species of smartweed (genus Persicaria) with a focus on drimane sesquiterpenoids. *Phytochemistry.* 2014;108:129–36. doi:10.1016/j.phytochem.2014.10.001.
 37. Hussain F, Ahmad B, Hameed I, Dastagir D, Sanaullah P, Azam S, et al. Antibacterial, antifungal and insecticidal activities of some selected medicinal plants of Polygonaceae. *Afr J Biotechnol.* 2010;9(31):5032–6.
 38. Derita M, Zacchino S. Validation of the ethnopharmacological use of Persicaria maculosa for its antifungal properties. *Nat Prod Commun.* 2011;p. 6–931.
 39. Smolarz HD, Potrzebowski MJ. Persilben, a new carboxystilbene from Persicaria maculosa. *J Mol Struct.* 2002;605(2-3):151–6. doi:10.1016/S0022-2860(01)00758-X.
 40. Smolarz HD, Kosikowska U, Baraniak B, Malm A, Persona A. Lipophilicity, antifungal and antioxidant properties of persilben. *Acta Pol Pharm.* 2005;62(6):457–62.
 41. Vasasa A, Lajtera I, Kúszna N, Forgó P, Jakabb G, Fazakasc C, et al. Flavonoid, stilbene and diarylheptanoid constituents of Persicaria maculosa Gray and cytotoxic activity of the isolated compounds. *Fitoterapia.* 2020;p. 104610. doi:10.1016/j.fitote.2020.104610.
 42. Fu L, Sun X, Gao Y, Chen R. Tannic acid: a novel calibrator for facile and accurate mass measurement of electrospray ionization mass spectrometry. *J Am Soc Mass Spectrom.* 2019;30(8):1545–49. doi:10.1007/s13361-019-02211-9.
 43. Abouelmagd SA, Ellah NH, Amen O, Abdelmoez A, Mohamed NG. Self-assembled tannic acid complexes for pH-responsive delivery of antibiotics: role of drug-carrier interactions. *Int J Pharm.* 2019;562:76–85. doi:10.1016/j.ijpharm.2019.03.009.
 44. Liu X, Kim J, Li Y, Li J, Liu F, Chen X, et al. Tannic acid stimulates glucose transport and inhibits adipocyte differentiation in 3T3L1 cells. *J Nutr.* 2005;135(2):165–71. doi:10.1093/jn/135.2.165.
 45. Afsana K, Shiga K, Ishizuka S, Hara H. Reducing effect of ingesting tannic acid on the absorption of iron, but not of zinc, copper and manganese by rats. *Biosci Biotechnol Biochem.* 2004;68(3):584–92. doi:10.1271/bbb.68.584.
 46. Wu Y, Zhong L, Yu Z, Qi J. Anti-neuro inflammatory effects of tannic acid against lipopolysaccharide-induced BV2 microglial cells via inhibition of NF- κ B activation. *Drug Dev Res.* 2019;80(2):262–8. doi:10.1002/ddr.21490.
 47. Soyocak A, Kurt H, Cosan DT, Saydam F, Calis IU, Kolac UK, et al. Tannic acid exhibits anti-inflammatory effects on formalin-induced paw edema model of inflammation in rats. *Hum Exp Toxicol.* 2019;38(11):1296–301. doi:10.1177/0960327119864154.
 48. Nie F, Liang Y, Jiang B, Li X, Xun H, He W, et al. Apoptotic effect of tannic acid on fatty acid synthase over-expressed human breast cancer cells. *Tumour Biol.* 2016;37(2):2137–43. doi:10.1007/s13277-015-4020-z.
 49. Ren Y, Li X, Han B, Zhao N, Mu M, Wang C, et al. Improved anti-colorectal carcinomatosis effect of tannic acid co-loaded with oxaliplatin in nanoparticles encapsulated in thermosensitive hydrogel. *Eur J Pharm Sci.* 2019;128:279–89. doi:10.1016/j.ejps.2018.12.007.
 50. Zhang J, Song Q, Han X, Zhang Y, Zhang Y, Zhang X, et al. Multi-targeted protection of acetaminophen-induced hepatotoxicity in mice by tannic acid. *Int Immunopharmacol.* 2017;47:95–105. doi:10.1016/j.intimp.2017.03.027.
 51. Zhang J, Cui L, Han X, Zhang Y, Zhang X, Chu X, et al. Protective effects of tannic acid on acute doxorubicin-induced cardiotoxicity: involvement of suPMression in oxidative stress, inflammation, and apoptosis. *Biomed Pharmacother.* 2017;93:1253–60.
 52. Maqsood S, Benjakul S. Retardation of haemoglobin-mediated lipid oxidation of Asian sea bass muscle by tannic acid during iced storage. *Food Chem.* 2011;124(3):1056–62. doi:10.1016/j.foodchem.2010.07.077.
 53. Jina W, Xuea Y, Xueb Y, Hanb X, Songc Q, Zhanga J, et al. Tannic acid ameliorates arsenic trioxide-induced nephrotoxicity, contribution of NF- κ B and Nrf2 pathways. *Biomed Pharmacoth.* 2020;126:110047. doi:10.1016/j.biopha.2020.110047.
 54. Hemmati AA, Olapour S, Varzi HN, Khodayar MJ, Dianat M, Mohammadian B, et al. Ellagic acid protects against arsenic trioxide-induced cardiotoxicity in rat. *Hum Exp Toxicol.* 2018;37:412–419.
 55. Ashafaq M, Sharma P, Khatoun S, Haque D, Tabassum H, Parvez S, et al. Heavy metal-induced systemic dysfunction attenuated by tannic acid. *J Environ Pathol Toxicol Oncol.* 2016;35(2):109–20. doi:10.1615/JEnvironPatholToxicolOncol.2016014527.
 56. Bargah RK. Preliminary test of phytochemical screening of crude ethanolic and aqueous extract of Moringa pterygosperma Gaertn. *J Pharmacogn Phytochemistry.* 2015;4(1):7–9.
 57. Ugochukwu SC, Uche A, Ifeanyi O. Preliminary phytochemical screening of different solvent extracts of stem bark and roots of Dennetia tripetala G. Baker. *Asian J Plant Sci Res.* 2013;3(3):10–3.
 58. Prabha SB, Rao M, Kumar MR. Evaluation of in vitro Antioxidant, Antibacterial and Anticancer activities of leaf extracts of Cleome rutidosperma. *Res J Pharm Tech.* 2017;10(8):2492–6. doi:10.5958/0974-360X.2017.00440.1.
 59. OECD, Organisation for Economic co-operation and Development. OECD guidelines for the testing of chemicals/Section 4: Health Effects Test No. 423: Acute oral Toxicity Acute Toxic Class method. OECD, 2002; Paris.
 60. Zeinvand-Lorestani H, Nili-Ahmadabadi A, Balak F, Hasanzadeh G, Sabzevari O. Protective role of thymoquinone against paraquat-induced hepatotoxicity in mice. *Pestic Biochem Physiol.* 2018;148:16–21. doi:10.1016/j.pestbp.2018.03.006.
 61. Ohkawa H, Ohishi N, Yagi K. Assay for lipid peroxides in animal tissues by thiobarbituric acid reaction. *Anal Biochem.* 1979;95(2):351–8. doi:10.1016/0003-2697(79)90738-3.
 62. Cardiff RD, Miller HC, Munn RJ. Manual hematoxylin and eosin staining of mouse tissue sections. *Cold Spring Harb Protoc.* 2014;2014(6):655–8. doi:10.1101/pdb.prot073411.
 63. Joan O, Barbara AF, Qing X, Samuel WF. He identification of stem cells in human liver diseases and hepatocellular carcinoma. *Exp Mol Pathol.* 2010;88(3):331–40. doi:10.1016/j.yexmp.2010.01.003.
 64. Gupta RK, Singh RK, Swain SR, Hussain T, Rao CV. Anti-hepatotoxic potential of Hedyotis corymbosa against D-galactosamine-induced hepatopathy in experimental rodents. *Asian Pac J Trop Biomed.* 2012;12:1542–7.
 65. Minaiyan M, Ghannadi A, Karimzadeh A. Anti-ulcerogenic effect of ginger (rhizome of Zingiber officinale Roscoe) on cystemine induced

- duodenal ulcer in rats. *J Pharm Sci.* 2006;14(2):97–101.
66. Raish M, Ahmad A, Alkharfy KM, Ahamad SR, Mohsin K, Al-Jenoobi FI, et al. Hepatoprotective activity of *Lepidium sativum* seeds against Dgalactosamine/lipopolysaccharide induced hepatotoxicity in animal model. *BMC Complementary Altern Med.* 2016;16:501. doi:10.1186/s12906-016-1483-4.
 67. Sharma UK, Kumar R, Ganguly R, Gupta A, Sharma AK, Pandey AK, et al. An active Component of Cinnamon provides Protection against Food colour induced Oxidative stress and Hepatotoxicity in albino Wistar rats. *Vegetos.* 2018;31(2):123–9. doi:67.U.K. Sharma, R. Kumar, R. Ganguly, A. Gupta, A.K. Sharma, A.K. Pandey, Cinnamaldehyde, An active Component of Cinnamon provides Protection against Food colour induced Oxidative stress and Hepatotoxicity in albino Wistar rats, *Vegetos* 2018;31: 123–129..
 68. Sharma UK, Sharma AK, Kumar R, Gupta A, Pandey A, Pandey AK, et al. Pharmacological activities of cinnamaldehyde and eugenol: antioxidant, cytotoxic and anti-leishmanial studies. *Cell Mol Biol.* 2017;63(3):73–8. doi:10.14715/cmb/2017.63.6.15.
 69. Kumar R, Gupta A, Singh A, Bishayee A, Pandey AK. Antioxidant and antihyperglycemic activities of bottlebrush plant (*Callistemon lanceolatus*) stem extracts. *Medicines.* 2020;7(3):11. doi:10.3390/medicines7030011.
 70. Okwu DE. Phytochemical and vitamin content of indigenous spices of South Eastern Nigeria. *J Sustain Agricultural Environ.* 2004;6(2):30–4.
 71. Raza H, John A. In vitro protection of reactive oxygen species induced degradation of lipids, proteins and 2-deoxyribose by tea catechins. *Food Chem Toxicol.* 2007;45(10):1814–20. doi:10.1016/j.fct.2007.03.017.
 72. Balasundram N, Sundram K, Samman S. Phenolic compounds in plants and agri-industrial by-products: antioxidant activity, occurrence, and potential uses. *Food Chem.* 2006;99(1):191–203. doi:10.1016/j.foodchem.2005.07.042.
 73. Kessler M, Ubeaud G, Jung L. Anti- and pro-oxidant activity of rutin and quercetin derivatives. *J Pharm Pharmacol.* 2003;55(1):131–42. doi:10.1211/002235702559.
 74. Dolara P, Luceri C, De Filipmo C. Red wine polyphenols influence carcinogenesis, intestinal microflora, oxidative damage and gene expression profiles of colonic mucosa in F344 rats. *Mutat Res.* 2005;591(1-2):237–46. doi:10.1016/j.mrfmmm.2005.04.022.
 75. Proestos C, Boziaris IS, Nychas GJE, Komaitis M. Analysis of flavonoids and phenolic acids in Greek aromatic plants: Investigation of their antioxidant capacity and antimicrobial activity. *Food Chem.* 2006;95(4):664–71.
 76. Lee YJ, Kim DB, Lee J, Cho JH, Kim B, Choi HS, et al. Antioxidant activity and anti-adipogenic effects of wild herbs mainly cultivated in Korea. *Molecules.* 2013;18(10):12937–50. doi:10.3390/molecules181012937.
 77. Halliwell B. Reactive oxygen species in living systems: source, biochemistry, and role in human disease. *Am J Med.* 1991;91(3C):14–22. doi:10.1016/0002-9343(91)90279-7.
 78. OECD. OECD Guidelines for the Testing of Chemicals, Test No. 236; Fish Embryo Acute Toxicity (FET) Test; OECD: Paris, France, 2013.
 79. Darbar S, Bhattacharya A, Chakraborty MR, Chattopadhyay S. Livina, a polyherbal preparation protects liver against aceclofenac-induced hepatic insult in sprague-dawley rats: a comparison with silymarin. *Pharmacologyonline.* 2010;2:889–907. doi:10.13140/RG.2.1.4431.4966.
 80. Darbar S, Bose A, Chattaraj TK, Pal TK. Protective role of *Zingiber officinale* Roscoe on aceclofenac induced oxidative stress in rat liver. *Int J Pharmtech Res.* 2010;2:495–501.
 81. Hamed MA, Ali SA, El-Rigal NS. Therapeutic potential of ginger against renal injury induced by carbontetrachloride in rats. *The Scientific World Journal.* 2012;p. 840421. doi:10.1100/2012/840421.
 82. Mccay PB, Lai EK, Poyer JL, Dubose CM, Janzen EG. Oxygen- and carbon-centered free radical formation during carbon tetrachloride metabolism observation of lipid radicals in vivo and in vitro. *J Biol Chem.* 1984;259(4):2135–43.
 83. Recknagel RO, Glende EA, Dolak JA, Waller RL. Mechanisms of carbon tetrachloride toxicity. *Pharm Ther.* 1989;43(1):139–54. doi:10.1016/0163-7258(89)90050-8.
 84. Pareek A, Godavarthi A, Issarani R, Nagori B. Badri Prakash Nagori; Antioxidant and hepatoprotective activity of *Fagonia schweinfurthii* (Hadidi) Hadidi extract in carbon tetrachloride induced hepatotoxicity in HepG2 cell line and rats. *J Ethnopharmacol.* 2013;150(3):973–81. doi:10.1016/j.jep.2013.09.048.
 85. Drotman RB, Lawhorn GT. Serum enzymes are indicators of chemical induced liver damage. *Drug Chemical Toxicol.* 1978;1(2):163–71. doi:10.3109/01480547809034433.
 86. Ploa GL, Hewitt WR. Principle and Methods of Toxicology. vol. II. Raven Press; 1989. p. 399–399.
 87. Clawson GA. Mechanism of carbon tetrachloride hepatotoxicity. *Pathol Immunopathol Res.* 1989;8(2):104–12. doi:10.1159/000157141.
 88. Sankar P, Telang AG, Manimaran A. Protective effect of curcumin on cypermethrin-induced oxidative stress in Wistar rats. *Exp Toxicol Pathol.* 2012;64(5):487–93. doi:10.1016/j.etp.2010.11.003.
 89. Najmi AK, Pillai KK, Pal SN, Aqil M. Free radical scavenging and hepatoprotective activity of jigrine against galactosamine induced hepatopathy in rats. *J Ethnopharmacol.* 2005;97(3):521–5. doi:10.1016/j.jep.2004.12.016.
 90. Arun K, Balasubramanian U. Comparative Study on Hepatoprotective activity of *Phyllanthus amarus* and *Eclipta prostrata* against alcohol induced in albino rats. *Int J Environ Sci.* 2011;2:361–79.
 91. Sharma UK, Kumar R, Gupta A, Ganguly R, Singh AK, Ojha AK, et al. Ameliorating efficacy of eugenol against metanil yellow induced toxicity in albino Wistar rats. *Food Chem Toxicol.* 2019;126:34–40. doi:10.1016/j.fct.2019.01.032.
 92. Hsiao G, Shen MY, Lin KH. Antioxidative and hepatoprotective effects of *Antrodia camphorata* extract. *J Agric J Agric Food Chem.* 2003;51(11):3302–8. doi:10.1021/jf021159t.

Author biography

Mohd. Shafi Dar, Research Scholar

Deepak Kumar Mittal, HOD, Zoology, SSSUTMS

Shazia Tabasum, Research Scholar

Cite this article: Dar MS, Mittal DK, Tabasum S. Antioxidant, Anti-inflammatory and hepatoprotective activities of *Persicaria maculosa* (linn.) and its active principle i.e tannic acid against Carbon tetrachloride induced oxidative stress and hepatotoxicity in wistar rats. *IP Int J Forensic Med Toxicol Sci* 2022;7(1):17-26.