

Content available at: <https://www.ipinnovative.com/open-access-journals>

IP International Journal of Forensic Medicine and Toxicological Sciences

Journal homepage: <http://www.ijfmts.com/>

Case Report

Fatal fall from height with self-inflicted wounds - A case of complex unplanned suicide

Dinesh Rao ^{1,*}

¹Dept. of Forensic Medicine, The Oxford Medical College Hospital and Research Centre, Bengaluru, Karnataka, India



ARTICLE INFO

Article history:

Received 04-03-2022

Accepted 08-03-2022

Available online 13-04-2022

Keywords:

Complex suicides

Unplanned suicides

Planned suicides

Fatal fall

Incised wound

ABSTRACT

A 32-year-old man Jumped to death from his multistoried apartment He had multiple deep incised wound on his left forearm and neck. The incident was concluded as suicide after a proper Police investigation, Crime Scene Investigation, Circumstances Analysis and Complete Autopsy. Although Suicides by Fall is not uncommon but associated multiple Deep incised Wounds on the Neck and Extremities is not Known, Though Self inflicted Incised wounds are frequently reported. We present this Rare and Unheard case of Complex and Unplanned Suicide, a combination of Deep incised Neck wounds and Extremity Wounds in a Fatal Fall. The Crime Scene investigation, the method employed, the autopsy findings and the interview with their relatives altogether pointed toward a suicidal etiology.

This is an Open Access (OA) journal, and articles are distributed under the terms of the [Creative Commons Attribution-NonCommercial-ShareAlike 4.0 License](#), which allows others to remix, tweak, and build upon the work non-commercially, as long as appropriate credit is given and the new creations are licensed under the identical terms.

For reprints contact: reprint@ipinnovative.com

1. Introduction

Suicide is the act of intentionally causing one's own death.¹ Some suicides are impulsive acts due to stress (such as from financial or academic difficulties), relationship problems (such as breakups or deaths of close ones), or harassment/bullying.²⁻⁴ The most commonly used method of suicide varies between countries, and is partly related to the availability of effective means.⁵ Common methods of suicide include hanging, pesticide poisoning, and firearms.^{2,6} Suicides resulted in 828,000 global deaths in 2015, an increase from 712,000 deaths in 1990.^{7,8} This makes suicide the 10th leading cause of death worldwide.^{9,10} Approximately 1.5% of people die by suicide.¹¹ In a given year this is roughly 12 per 100,000 people.¹⁰ There is no known unifying underlying pathophysiology for suicide.¹² It is however believed to result from an interplay of behavioral, socio economic and psychological factors.⁵ Low levels of brain-

derived neurotrophic factor (BDNF) are both directly associated with suicide¹³ and indirectly associated through its role in major depression, posttraumatic stress disorder, schizophrenia and obsessive-compulsive disorder.¹⁴ Post-mortem studies have found reduced levels of BDNF in the hippocampus and prefrontal cortex, in those with and without psychiatric conditions.¹⁵ Serotonin, a brain neurotransmitter, is believed to be low in those who die by suicide.¹⁶

Generally, Suicides are Divided into Simple and Complex Suicides. When One Method adopted to End the Life is called Simple Suicide, the Majority Type. When More Than one Methods applied to end the Life it is called Complex Suicide.¹⁷ Complex Suicides form 1-1.5% of the total suicides.^{18,19} When more than one methods applied simultaneously to end the life it is called planned suicide and if More than one method applied after a failed method is called Unplanned method.^{20,21} If more than One Method applied to end the Life, this complexity in the different Nature and Pattern of injuries poses serious challenge to the Pathologist and the investigating Officer

* Corresponding author.

E-mail address: dineshrao22@yahoo.com (D. Rao).

to differentiate it from Suicide and Homicide. Hence, we present in this article a rare reported complex and Unplanned Suicide, wherein the Individual used Three Different Methods to end his life. This article also highlights the Importance of Complete Autopsy Examination, Crime Scene Examination, Police Investigation and Circumstances to arrive at the exact Cause and Manner of Death.^{22,23}

2. Case Report

A 32years male jumped to death from his 5th floor apartment. The Investigating officer confirmed that there as pool of blood in his apartment and the doors were broken open to gain access to his apartment. He committed this act in the absence of his family members, earlier unsuccessful attempts in the form of Insecticide Consumption and Failed Suspension by Neck were also Present. A two-page Suicide note was also recovered from his room. He was brought dead to the Hospital, he had died on the spot. An enquiry with his friends and family members revealed his unusual behavior in the recent months, lack of interest in his family friends and sleeplessness. He had frequent fights in his work place and known Financial worries At the autopsy, external examination showed Three different patterns and Nature of Injuries distributed over the Left side, of which One group were Fatal in Nature. One Pattern was noticed over his Left Forearm proximal to the Wrist consisting of Three Deep Incised wound, parallel to each other as seen in Figure 1, each tapering to the medial margins were uniform in length and depth as limited to the Muscular layer.

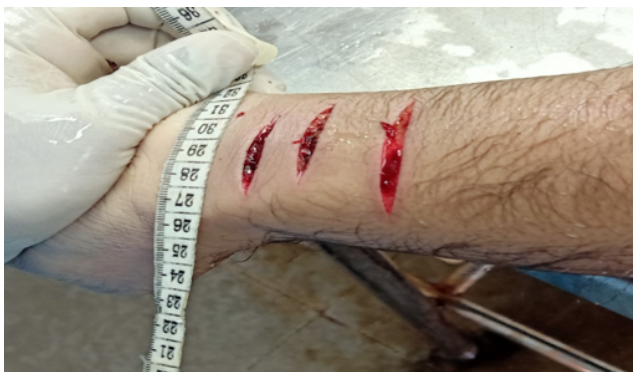

Fig. 1: Picture showing multiple linear and parallel self-inflicted deep incised wounds of the ventral aspect of left forearm.

Another Set of injuries were Four, Nearly Horizontal Deep incised Wounds situated above the Thyroid Cartilage over the Right side Neck as seen in Figure 2. Each Deep Incised wounds were associated 3-4 superficial incised wounds each on average measured 5cmsx0.2cms and their depths were limited to the Muscular Layer Except one in the front which severed the Anterior Jugular Vein. The Carotids and Internal Jugular Vessels and Respiratory Passage were Intact. Another pattern of injuries were Blunt Lacerated

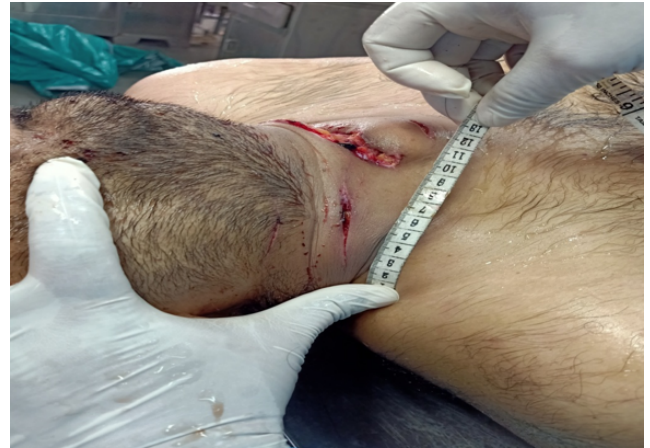

Fig. 2: Picture showing multiple nearly horizontal and parallel self-inflicted superficial & deep incised wounds of the neck.

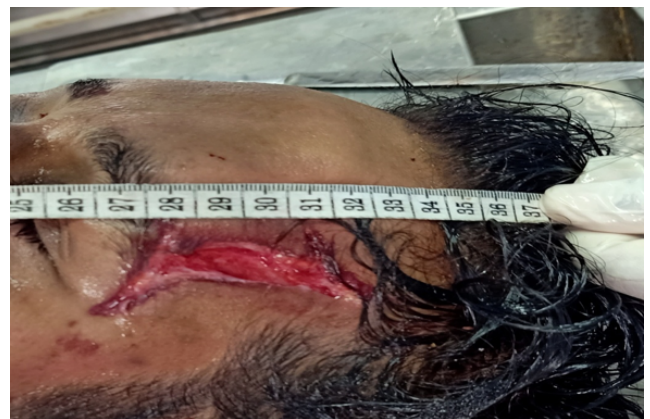

Fig. 3: Picture showing laceration across the left frontal scalp as a result of fall from height.

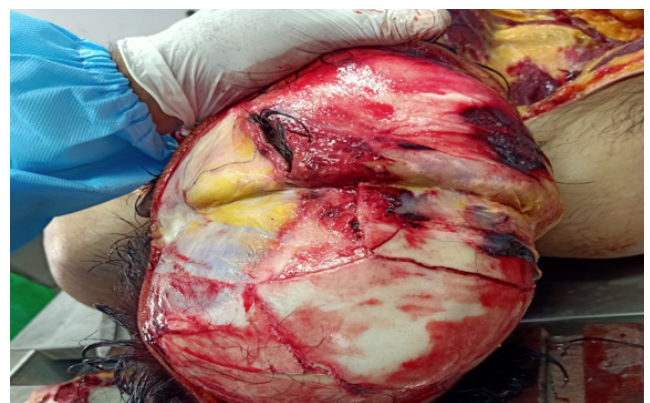


Fig. 4: Picture showing comminuted fracture underlying laceration of the left fronto parietal skull as a result of fall from height.

type as seen over the Head[Figure 3], Left Upper limb and Chest region, with Fracture Skull[Figure 4] and Laceration of Brain, Fracture of both sides Ribs noted at the Angles of the Ribs and Left Humeri mid shaft region. Toxicological Analysis revealed 48mg of Ethyl alcohol in Blood. The Investigative Report on the Suicide note confirmed the Deceased Authorship and Fingerprints from the death scene ruled out external invasion, the doors locked form inside further confirmed the same. Closed Circuit Television confirmed the Self Fall. All this ruled out Accidental and homicidal Nature of Act and further confirmed the Suicidal act of the individual.

3. Discussion

Majority of the Suicides reported are Simple in Nature, i.e. The Suicide adopt a single means of Ending Life, whereas in few cases the Suicide applies more than One method either simultaneously or one after the other to end their Lives, This was called as Complex Suicides. The present cases falls into the Latter, the Unplanned Complex Type, here the Individual failed in his attempt to end life by inflicting Multiple Incised wound over his left Forearm and by making other attempt to Inflicted Deep Cut Throat Incised Wounds over his Neck, and when all this Attempts failed to end his Life, he Finally Jumped from his Fifth Floor apartment to end his Life causing serious Fatal Injuries to his Head and Chest Region. Hence the Deceased applied more than One Method to end his Life, which is rarely seen in Suicide, this make the job of the Investigating Officer and The Pathologist Difficult because this Complex and Unplanned Methods pose a serious challenge to make the Distinction between Suicide and Homicide.²⁴ The Layer by Layer Dissection and exploration of the Neck Injuries and The Incised wounds over the Forearm further confirmed the Superficial Nature of the Wounds and also reflected the Intentions of the Suicide to adopt less painful methods and gradually preferring more Lethal Methods to end his Life. This is the Usual Character of and Individual seen in Complex Unplanned Suicides.²⁵ All this are another indication of Suicidal Nature of the Act, which differentiates itself from Accidental and Homicidal Nature of Act. In the Present case the Presence of CCTV Evidence, Suicide Note, The Circumstances and The Locking of the Door From Inside and Absence of External Finger prints all confirms the Suicidal Nature of the Act. The toxicological analysis had confirmed 48mg of Alcohol and also ruled out substance abuse.

Hence this Case illustrates the possibility of Different Methods employed by the Suicide to commit Suicide ,it also demonstrates the Determination and the Mental Makeup of the Individual to end his Life. Hence a Complete Autopsy Examination, Death Scene Examination and analysis of the Circumstances is always essential to understand the Complexity involved in the suicides of this Nature.

4. Conclusion

In all cases of Complex Planned or Unplanned Suicides wherein More than one Methods are attempted to end Lives, it is essential that the Conclusions should always be Drawn on the Cumulative results of the outcome of the Crime Scene Investigation, Pathologist Examination, Police Reports and the Circumstantial Evidence.

5. Conflict of Interest

The authors declare that there is no conflict of interest.

6. Source of Funding


None.

References

1. Stedman's Medical Dictionary. 28th Edn. Philadelphia: Lippincott Williams & Wilkins; 2006.
2. Suicide Fact sheet N°398". WHO. April 2016. Archived from the original on 4 March 2016. Retrieved 3 March 2016.
3. Bottino SM, Bottino CM, Regina CG, Correia AV, Ribeiro WS. Cyberbullying and adolescent mental health: systematic review. *Cad Saude Publica*. 2015;31(3):463–75. doi:10.1590/0102-311x00036114.
4. "Suicide rates rising across the U.S. | CDC Online Newsroom | CDC". www.cdc.gov. 11 April 2019. Retrieved 19 September 2019. Relationship problems or loss, substance misuse; physical health problems; and job, money, legal or housing stress often contributed to risk for suicide.
5. Yip PS, Caine E, Yousuf S, Chang SS, Wu KC, Chen YY, et al. Means restriction for suicide prevention. *Lancet*. 2012;379(9834):2393–9. doi:10.1016/S0140-6736(12)60521-2.
6. Ajdacic-Gross V, Weiss MG, Ring M, Hepp U, Bopp M, Gutzwiller F, et al. Methods of suicide: international suicide patterns derived from the WHO mortality database. *Bull World Health Organ*. 2008;86(9):726–32.
7. Wang H, Naghavi M, Allen C, Barber RM, Bhutta ZA, Carter A, et al. (GBD 2015 Mortality and Causes of Death Collaborators) (October 2016). "Global, regional, and national life expectancy, all-cause mortality, and cause-specific mortality for 249 causes of death, 1980–2015: a systematic analysis for the Global Burden of Disease Study 2015". *Lancet*. 2015;388(10053):1459–44.
8. Naghavi M, Wang H, Lozano R, Davis A, Liang X, Zhou M, et al. Global, Regional, And National Age–sex Specific All-cause And Cause-specific Mortality For 240 Causes Of Death, 1990–2013: A Systematic Analysis For The Global Burden Of Disease Study 2013. *Lancet*. 2013;385(9963):117–71. doi:10.1016/S0140-6736(14)61682-2.
9. Hawton K, Van Heeringen K. Suicide. *Lancet*. 2009;373(9672):1372–81.
10. Várník P. Suicide in the World. *Int J Environ Res Public Health*. 2012;9(3):760–71. doi:10.3390/ijerph9030760.
11. Fazel S, Runeson B. Suicide. *N Engl J Med*. 2020;382(3):266–74. doi:10.1056/NEJMr1902944.
12. Chang B, Gitlin D, Patel R. The depressed patient and suicidal patient in the emergency department: evidence-based management and treatment strategies. *Emerg Med Pract*. 2011;13(9):1–23.
13. Pjevac M, Pregelj P. Neurobiology of suicidal behaviour. *Psychiatr Danub*. 2012;24(3):S336–41.
14. Sher L. The role of brain-derived neurotrophic factor in the pathophysiology of adolescent suicidal behavior. *Int J Adolesc Med Health*. 2011;23(3):181–5.

15. Sher L. Brain-derived neurotrophic factor and suicidal behavior. *QJM*. 2011;104(5):455–8. doi:10.1093/qjmed/hcq207.
16. Yanowitch R, Coccaro EF. The neurochemistry of human aggression. *Adv Genet*. 2011;75:151–69. doi:10.1016/B978-0-12-380858-5.00005-8.
17. Marcinkowski T, Pukacka-Sokolowska L, Wojciechowski T. Wojciechowski Planned complex suicide. *Forensic Sci*. 1974;3(1):95–100. doi:10.1016/0300-9432(74)90013-2.
18. Pollak S. Zur Morphologie der Bolzenschußverletzung. *Z Rechtsmedizin*. 1977;80(2):153–65. doi:10.1007/BF00200885.
19. Bohnert M, Tsokos M. Forensic Pathology Reviews. *Forensic Pathol Rev*. 2005;2:127–43. doi:10.1385/1-59259-872-2:127.
20. Toro K, Pollak S. Complex suicide versus complicated suicide. *Forensic Sci Inter*. 2009;184(1-3):6–9. doi:10.1016/j.forsciint.2008.10.020.
21. Cascini F, Longo F, Polacco M, Scafetta I. Foreign object ingestion in complex suicide: A case report and review of the literature. *Forensic Sci inter*. 2012;219(1-3):e1–3. doi:10.1016/j.forsciint.2011.11.015.
22. WHO. Preventing suicide: a global imperative. vol. 7; 2014. p. 7,20,40. Available from: <https://www.who.int/publications/i/item/>9789241564779.
23. Suicide across the world (2016)". World Health Organization. ; 2016.
24. Germerott T, Jaenisch S, Hatch G, Al UV, Detlef G. Planned complex suicide: Self-strangulation and plaster ingestion. *Forensic Sci Inter*. 2010;202(1-3):e35–7. doi:10.1016/j.forsciint.2010.04.053.
25. Taff ML, Boglioli LR, Danto BL. Planned complex suicide. *Am J Forensic Med Pathol*. 1998;19(2):194. doi:10.1097/00000433-199806000-00020.

Author biography

Dinesh Rao, Professor & HOD (Forensic Medicine)
 <https://orcid.org/0000-0002-7636-0198>

Cite this article: Rao D. Fatal fall from height with self-inflicted wounds - A case of complex unplanned suicide. *IP Int J Forensic Med Toxicol Sci* 2022;7(1):32-35.