

Content available at: <https://www.ipinnovative.com/open-access-journals>

IP International Journal of Forensic Medicine and Toxicological Sciences

Journal homepage: <http://www.ijfmts.com/>

Original Research Article

Determination of age by radiological examination of shoulder joint

D.S. Saravanan¹, R. Julius¹, S. Angayarkanni^{1,*}¹Dept. of Forensic Medicine, Madras Medical College, Tamil Nadu, India

ARTICLE INFO

Article history:

Received 02-08-2022

Accepted 10-09-2022

Available online 15-10-2022

Keywords:

Age estimation
Secondary center
Shoulder joint
Radiograp

ABSTRACT

Aim: Aim of the study was to estimate the age of an individual from the fusion of the secondary ossification center of the shoulder joint.**Materials and Methods:** The study was conducted on 60 subjects who were randomly selected from various schools as well as the cases attending the outpatient Department of General Medicine, Rajiv Gandhi Government General Hospital, Madras Medical College, Chennai. After obtaining written consent from each individual, radiological examination was done.**Observations:** After the statistical analysis it was observed that in the age group 16-17 males, there were no complete union, among females in the same age group. It was 30%, in the age group 17-18, percentage of complete union was 30.76 among males and 40% among females, in the age group 18-19, percentage of complete union was 33.33% among males and 50% among females.**Conclusion:** It was concluded that the age of complete fusion of epiphysis of the shoulder joint was 17-18 years for males and 16-17 years for females and the earliest union occurred at the age of 15 years in females and 17 years in males which was higher than the previous studiesThis is an Open Access (OA) journal, and articles are distributed under the terms of the [Creative Commons Attribution-NonCommercial-ShareAlike 4.0 License](https://creativecommons.org/licenses/by-nc-sa/4.0/), which allows others to remix, tweak, and build upon the work non-commercially, as long as appropriate credit is given and the new creations are licensed under the identical terms.For reprints contact: reprint@ipinnovative.com

1. Introduction

Identification means determination of individuality of a person. Identification is very important to be determined both in living and the dead person. Fixing up of the individuality of a person has got its own significance in civil cases like inheritance of property, passport, missing persons, disputed sex, marriage or in criminal cases like identification of a accused in criminal offences of murder, dacoit, sexual offences etc. Age estimation cases are often referred to forensic experts as it is very important issue to the court of law and to common man.¹

In both criminal and civil cases estimation of age of an individual is one of the difficult problems faced by forensic experts. Whether it is a case of living, dead or human remains it always creates trouble in court of law. In cases

where authorities are in doubt about the age of a suspected criminal, forensic age estimation is often requested in order to determine if the suspect is of an age in which he may be charged with a crime.²

The age of an individual can be determined from teeth, ossification of bones, and secondary sex characteristics and general development in case of children.³ Determination of age of an individual from Epiphyseal union is a well-accepted fact in the field of medical and legal professions. Epiphysis of the bone unites during age periods which are remarkably constant for a particular epiphysis.⁴ It is an established fact that the sequence and ultimate ossification of epiphyses varies in both sexes in different part of world to the extent that there are wide variation even in the population of the different states of the same country.⁵ Taking into account of this variation, the present study is to estimate the age of an individual and the average fusion

* Corresponding author.

E-mail address: dr.angai5774kayal@gmail.com (S. Angayarkanni).

of secondary ossification center of shoulder joint

2. Aims and Objectives

1. To estimate the age of an individual from the fusion of the secondary ossification center of the shoulder joint.
2. To study the average age of fusion of the secondary ossification center of the shoulder joint.

3. Materials and Methods

After obtaining written consent for their radiological examination, the persons selected for study were grouped as per their stated age namely 16-17 years, 17-18 years and 18-19 years. The persons belonging to the age group selected from either gender are included in the study irrespective of their socio- economic, religious and educational status. Age as stated by them is further confirmed by birth certificate or entry in their school record. Each person is X-rayed for shoulder joint & subsequently the skiagrams are studied in detail in reference to various ossification centers, their appearance, process of fusion and post fusion scarring. Subject selection: People should be living in Chennai regions for greater than 5 years. Inclusion Criteria: Persons aged 16-19 years and should have accurate record of their Date of Birth. .Exclusion Criteria: They should be free from any physical debility. As per the observations and analysis of previous studies based on radiological assessment of degree of fusion of epiphysis of shoulder joint in this study, X ray antero-posterior view was taken to study the fusion of shoulder joint. Ossification process at the shoulder joint was divided into the following grades: a. Centre not appeared. b. Centre appeared but incomplete. c. Union started but incomplete. d. Complete Union. Criteria for fusion: (a) There should be no gap or defect in the epiphyseodiaphyseal region of the bone. (b) There should be no discontinuity in the outline of the bone. (c) Presence of epiphyseal scar in considered as fused. Criteria for non-fusion: There should be a clear gap or defect which resembles a fracture line between epiphysis and diaphysis of the bone. Even a small defect in any of the two sides of the bone is considered as 'not fused'. Results were tabulated.

4. Analysis of Results

60 Radiographs in the age group of 16-19 years were analyzed, of which 30 were male and 30 were female.

5. Discussion

5.1. Ossification of shoulder joint

The center of the humerus appears during the first year of life. For the greater tubercle during the 2nd year and for lesser tubercle by 5 years. The three centers unite to form a compound epiphysis by 6 years, which unites with the shaft at 13 – 17 years in females and about 16 – 20 years

in females. The corocoid and acromion both ossify from separate centers, which are readily visible on radiographs. The center for the tip of corocoid process appears about at 13 years and unites by 20 years. The center at the tip of acromion appears around 15 years and unites between 18 and 20 years. It is possible to determine the approximate age of an individual by radiological examination of bones till the ossification completes.

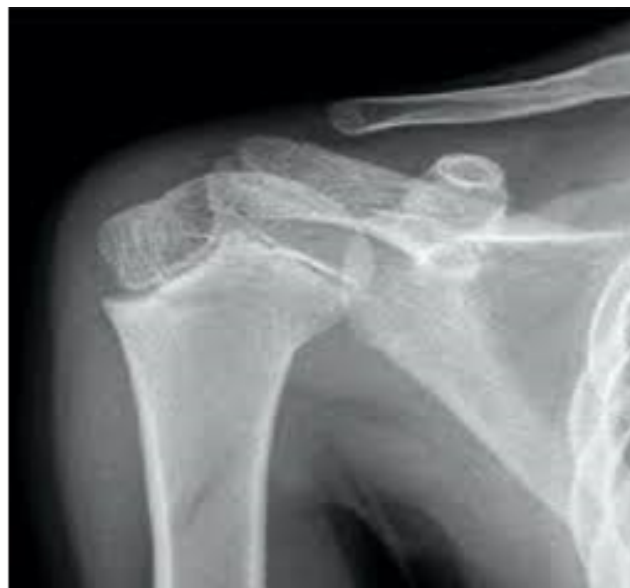

Fig. 1: X-ray Shoulder joint - unfused

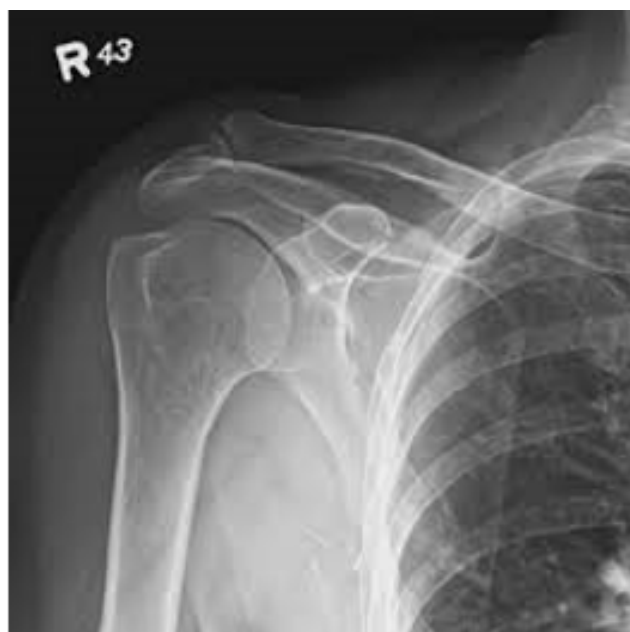

Fig. 2: X-ray shoulder joint – fused

In the present study, the skeletal maturity at the shoulder joint of known chronological age of the Tamil Nadu population was analyzed.

21 radiographs in the age group of 16 – 17 years were analyzed of which 11 were male and 10 were female. Secondary ossification center showed no union in 4 cases in the age group of 16 - 17 years. i.e 4 cases (36.34%) were in stage I. 4 cases (36.34%) were in stage II i.e (Showed beginning of union) 3 cases (27.27%) were in stage III i. e (Showed recent union). None of them (0%) showed complete union of the secondary ossification center in the age group of 16 – 17 years among males.

Secondary ossification center showed no union in 2 cases (20%) in the age group of 16 – 17 years among females. i.e 2 cases were in stage I. 2 cases (20%) were in stage II i.e (showed beginning of union) 3 cases (30 %) were in stage III i.e (showed recent union) 4 cases (40 %) were in stage IV i.e (showed complete union).

23 radiographs in the age group of 17 - 18 years were analyzed of which 13 were male and 10 were female. Secondary ossification center showed no union in 3 cases (23.07%) in the age group of 17 - 18 years among males. I.e 3 cases were in stage I - 3 cases (23.07%) were in stage II i.e (showed beginning of union) 3 cases (23.07%) were in stage III i.e (showed recent union) 4 cases (30.76%) were in stage IV i.e (showed complete union) Secondary ossification center showed no union in one case (10%) in the age group of 17 – 18 years among females. 2 cases (20%) were in stage II i.e (showed beginning of union) 3 cases (30%) were in stage III i.e (showed recent union) 4 cases (40%) were in stage IV i.e. (showed complete union) 16 radiographs in the age group of 18 - 19 years were analyzed of which 6 were male and 10 were female. Secondary ossification center showed no union in one case (16.66%) in the age group of 18 – 19 years among males. 1 case (16.66%) were in stage II i.e. (showed beginning of union) 2 cases (33.33%) were in stage III i.e. (showed recent union) 2 cases (33.33%) were in stage IV i.e. (showed complete union) Secondary center showed no union in 0% of cases (stage I) in the age group of 18 - 19 years among females. 2 cases were in stage II i.e. (showed beginning of union) 3 cases were in stage III i.e. (showed recent union) 5 cases were in stage IV i.e. (showed complete union) In the present study, majority of cases showed complete union of epiphysis at shoulder is seen by 17-18 years in males and 16-17 years in females. The present study signifies that epiphyseal centers in females mature 1-2 years earlier than in males. This observation correlates with the previous studies.^{4,6} In the comparative analysis from previous studies done by Reddy (Andhra Pradesh, 1973).³ Saini (Jaipur, 2005),⁷ Pimple (Mumbai, 2013),⁶ Flecker (Melbourne, 1932),⁸ there were significant number of cases the age of fusion of shoulder joint is 18-19 years in male.

Table 1: Sample distribution among males and females

Age Group	Male	Female	Total
16-17	11	10	21
17-18	13	10	23
18-19	06	10	16

Table 2: Stage of fusion of epiphysis of shoulder joint

Stage	I	II	III	IV
16-17	06	06	06	03
17-18	04	05	06	08
18-19	01	03	05	07

Table 3: Stage of fusion of the epiphysis of shoulder joint among females

Stage	I	II	III	IV
16-17	02	02	02	03
17-18	01	02	03	04
18-19	00	02	03	05

Table 4: Stage of fusion of the epiphysis of shoulder joint among males

Stage	I	II	III	IV
16-17	04	04	03	00
17-18	03	03	03	04
18-19	01	02	02	02

Table 5: Age of incidence of complete union

Age group (years)	No. of cases	% of male cases with complete union	% of female cases with complete union
16-17	21	0%	30%
17-18	23	30.76%	40%
18-19	16	33.33%	50%

Sample distribution among male and female

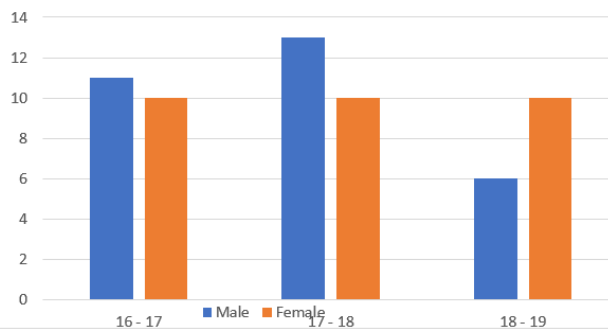


Diagram 1: Sample distribution among male and female

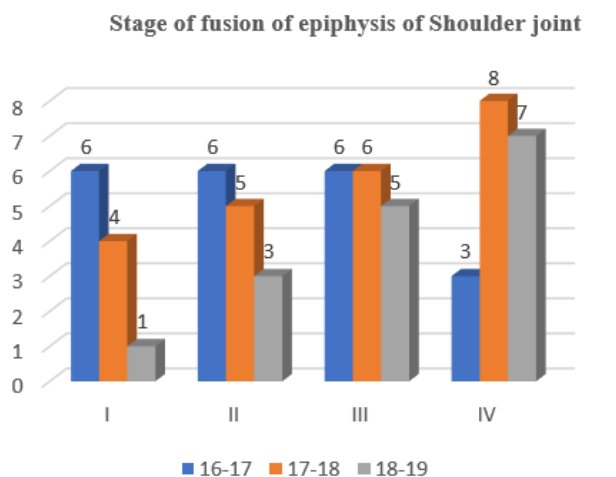


Diagram 2: Stage of fusion of epiphysis of shoulder joint

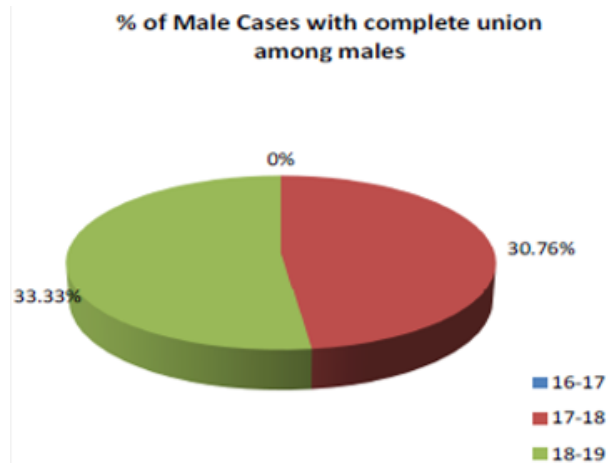


Diagram 5: % of male cases with complete union among males

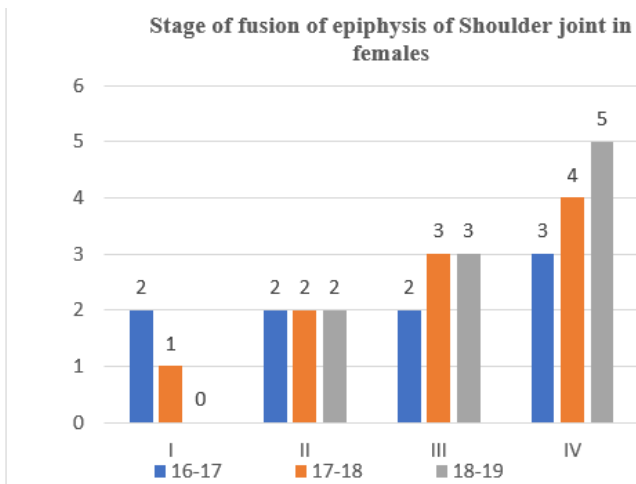


Diagram 3: Stage of fusion of epiphysis of shoulder joint in females

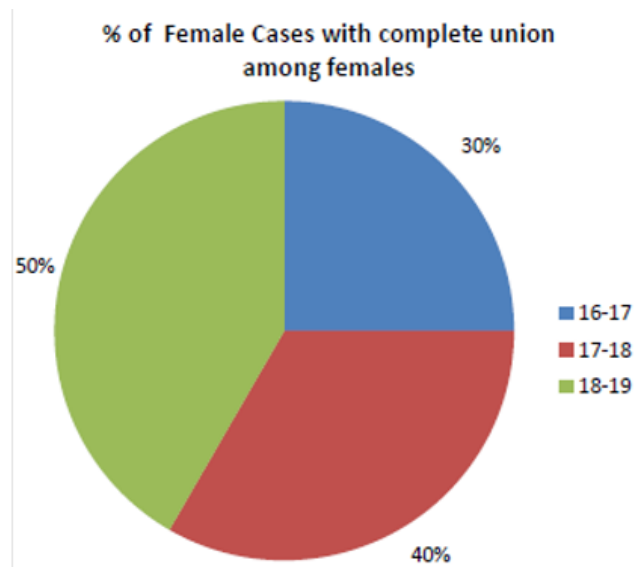


Diagram 6: % of females cases with complete union among females

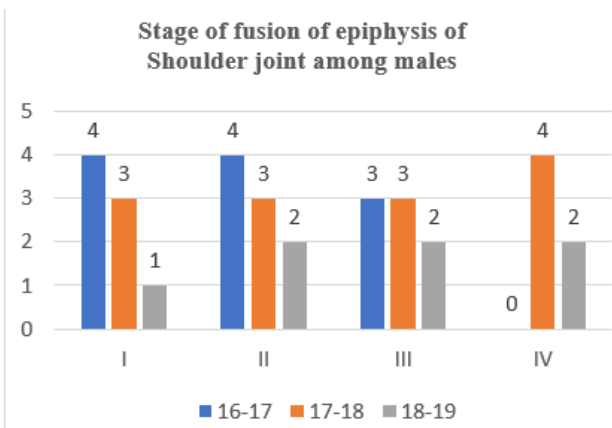


Diagram 4: Stage of fusion of epiphysis of shoulder joint among males

6. Ages of Medicolegal Importance

Almost every age is important from a medico-legal perspective. The example in this paper give only a glimpse of the full range of ages which a practicing medico legist may be asked to give opinion. These will vary from country to country mad even within various states of the country. It would be helpful for a particular medico legist of a particular state or country to compile his/her list in accordance with his/her own laws. An illustration of some of the ages with medico-legal importance are given below: For the approximate estimation of age, the following paragraphs should be correlated.

6.1. First fifteen days

The changes in the umbilical cord and the skin.

6.2. First six months

Weight and the height, anterior fontanelle closure and fusion of the two halves of mandible. The ossification centres in the capitata appears during second month after birth.

6.3. Six months to two years

The eruption and calcification of temporary teeth is the best guide and the appearance of the ossific centres and their size in heads of carpus, humerus, femur and the tarsus.

6.4. Two to six years

Ossification of the tarsus and carpus and appearance of centres in epiphysis of long bones. The number of carpal bones seen on radiographs indicate the approximate age in years in the age group of 2 – 6 years.

6.5. Six to thirteen years

Eruption and calcification of the permanent teeth is very helpful. Centres that have already appeared may prone to alterations and additional centres appear.

6.6. Thirteen and sixteen years

The changes of puberty and ossification of bones, especially in the region of the elbow joint.

6.7. Sixteen to 25 years

The epiphyses of most of the long bones unite with the shafts. The union of the epiphysis of ends of ribs, clavicles and iliac crest during this period. Between 20 – 30 years, incisors, tips of canines and cusps of premolars show slight to moderate wear. In the early twenties, the sternal rib shows a scalloped rim around a deepening V-shaped pit in both sexes.

6.8. To 35 Years

The saggital, coronal and lambdoid sutures of the skull start to close. The changes in the symphysis pubis are very important.

6.9. TO 50 Years

There is further progress in the changes in the symphysis of pubis. Between 30 to 40 years, tooth cusp wear may be moderate to severe. The medullary cavity of the humerus may have increased upward to the level of the lower end of the tuberosity. Wrinkles about the eyes, eyebrows and in

front of the ears appear about 35 to 40 years. About forty years, the Xiphoid process unites with the sternum. Between 40 – 50 years, vault sutures are all united both ectocranially and endocranially. The cortex of the long bones becomes less dense and thinner. The medullary cavity may extend upward to almost surgical neck in the humerus. Large sized atrophic areas in the iliac fossa and scapula appear. The inner borders of the ischial tuberosities and the lumbar vertebral margins show lipping by 40 years, which becomes well marked by 45 years. By the end of the fifth decade, bony projections from the superior and inferior margins of the rib is appears well in males, and the pit deepens and widens. In the females, the pit is relatively shallow and the bone itself is thinner. Ossification of the laryngeal and costal cartilages with that of hyoid bone usually begin. Bony articular surfaces show changes earlier. They include joint space reduction, lipping and the presence of punched out areas of osteoporosis on radiological examination. Ivory-like to granular appearance and feel of the skull bones appear.

6.10. TO 60 Years

The external tables of the vault become slightly thinner. The molar crowns of the teeth are usually worn flat to a single plane. The crown of all the molar cusps appears in a flat plane, an age of fifty plus is considered.

6.11. After sixty years

Further closure of sutures of skull occurs. In the fifties and sixties, small osteophytic spurs or spikes occur in the linea and tuberosities of muscle attachment which usually becomes well advanced in the seventies. osteoporosis is more marked and changes in the joint becomes well marked in character. The joint between the body of the sternum and the manubrium may fuse and the calcification of the tracheal and laryngeal cartilages become more visible. The pathological skeletal changes are the predominant changes of this period. The hair may become silvery white. The lower and upper jaws becomes completely edentulous usually around the age of 70 years.

7. Conclusion

Radiological examination of the ossification activates of the bones helps to determine the approximate age of an individual. Age can be determined only in terms of range of two to five years based on the appearance and fusion of the ossification centers. On examination 60 radiographs of the shoulder joint the age of complete fusion of epiphysis of the shoulder joint is 17-18 years for males and 16-17 years for females. Earliest union occurred at the age of 15 years in females and 17 years in males.

In the present study, the age group of complete fusion is higher than the previous studies. The reason for

this difference may be the geographical, nutritional and endocrine factors which influence the skeletal maturity. Age estimation from teeth, skull and pelvis has been done conventionally but each method has its own limitation and they are influenced by endocrine, racial, dietary and sex factors. These methods can be used to categorize age into broad age groups. Estimation of age based on fusion of epiphysis of shoulder joint plays a vital role in forensic age diagnosis of living adolescents and young adults. Sex difference is noted in the age of fusion of epiphysis of shoulder joint by 1-2 years. Females show 2 years earlier onset of fusion than males.

8. Ethical Clearance

Taken from Institutional Ethical committee

9. Source of Funding

None.

10. Conflict of Interest

None.

References

1. Dixit SP, Bansal RK. Study of ossification centers fusion of elbow joint in 15 to 17 years Garhwali females of Deharadun region. *J Indian Acad Forensic Med.* 2014;36(4):396-8.
2. Santoro V, Donno AD, Marrone M, Campobasso CP, Introna F. Forensic age estimation of living individuals: A retrospective analysis. *Forensic*

- SciInt.* 2009;15(1-3):129-30.
3. Reddy K, Murthy OP. *The Essentials of Forensic Medicine & Toxicology.* Jaypee Brothers Publications Ltd; 2017. p. 57-68.
4. Mazumder A, Nagrale N. Estimation of Age from Shoulder Joint by Radiographic Assessment of Epiphyseal Fusion of Related Bones in Population of Chhattisgarh: A Cross Sectional Study. *Med Legal Update.* 2019;19(2):7-11.
5. Singh A, Singh DK, Paricharak DG. Estimation of age by Radiological examination of distal end of humerus;. *J Evolution Med Dent Sci.* 2014;3(35):9286-9303.
6. Pimple DH, Waghmare VN. Fixation of 18 years of Age by Radiological Study of Shoulder Joint. *Int J Sci Res.* 2012;2(5):432-3.
7. Buri S, Saini PK, Joshi A, Garg M. Determination of Age from Epiphyseal Union of Bones at Shoulder Joint in Boys in Bikaner Region. *J Med Sci Clin Res.* 2017;5(3):1-5.
8. Flecker H. Roentgenographic Observations of the Times of Appearance of Epiphyses and their Fusion with the Diaphyses. *J Anat.* 1932;67(1):163-4.

Author biography

D.S. Saravanan, Senior Assistant Professor

R. Julius, Senior Assistant Professor

S. Angayarkanni, Senior Assistant Professor

Cite this article: Saravanan DS, Julius R, Angayarkanni S. Determination of age by radiological examination of shoulder joint. *IP Int J Forensic Med Toxicol Sci* 2022;7(3):94-99.