

Content available at: <https://www.ipinnovative.com/open-access-journals>

IP International Journal of Forensic Medicine and Toxicological Sciences

Journal homepage: <http://www.ijfmts.com/>

## Case Report

# An autopsy case of carbon monoxide poisoning: A case report

Kalpesh Chaudhari<sup>1</sup>, Jitendra Rathod<sup>2</sup>, O Gambhir Singh<sup>3,\*</sup>

<sup>1</sup>Dept. of Forensic Medicine, Government Medical College, Surat, Gujarat, India

<sup>2</sup>Dept. of Forensic Medicine, MP Shah Medical College, Jamnagar, Gujarat, India

<sup>3</sup>Dept. of Forensic Medicine, A.I.I.M.S, Kalyani, West Bengal, India



### ARTICLE INFO

#### Article history:

Received 10-03-2023

Accepted 30-03-2023

Available online 04-05-2023

#### Keywords:

Asphyxia

Carbon monoxide poisoning

Closed space

Accidental death

Silent Killer

### ABSTRACT

Asphyxial death from Carbon monoxide (CO) poisoning is occasionally reported in India. Here in this case report we present such a case of accidental CO poisoning. It was a case of a man aged about 38 years old contractor who succumbed to CO poisoning during sleep on a fateful night. He was a chain smoker with occasional alcohol consumption. The incident occurred inside a bed room which was latched from inside. He was found dead lying on the floor by the side of a semi burnt mattress. There are very few case reports on such poisoning cases that's the main reason of presenting this article.

This is an Open Access (OA) journal, and articles are distributed under the terms of the [Creative Commons Attribution-NonCommercial-ShareAlike 4.0 License](https://creativecommons.org/licenses/by-nc-sa/4.0/), which allows others to remix, tweak, and build upon the work non-commercially, as long as appropriate credit is given and the new creations are licensed under the identical terms.

For reprints contact: [reprint@ipinnovative.com](mailto:reprint@ipinnovative.com)

## 1. Introduction

Carbon monoxide (CO) is an odourless, colourless, tasteless, and non-irritating highly toxic gas.<sup>1</sup> This makes it difficult for those who are exposed to detect it. Because of it, this gas is also known as the "Silent Killer".<sup>2</sup> This gas is commonly formed during the incomplete combustion of organic materials. However, the most common sources of CO gas are faulty, poorly maintained, or inadequately ventilated gas appliances such as heaters or stoves, generators, grills or residential fires.<sup>3-5</sup>

CO gas has very high affinity for oxygen present in the haemoglobin. It has approximately 240 times the affinity of oxygen for binding to haemoglobin.<sup>6</sup> It forms the compound COHb which impairs tissue oxygen delivery, inhibits mitochondrial oxidative phosphorylation, and inactivates cytochrome oxidase.<sup>7</sup>

The carbon monoxide gas poisoning mainly affects the brain and the heart. Though it may cause some clinical features like headache, dizziness, nausea, vomiting,

shortness of breath, etc. mostly it causes silent death. It is more dangerous especially with people who are asleep, unconscious, drunk or drugged.<sup>6</sup>

## 2. Case History

Dead body of 38 years old male was brought to the autopsy room of FMT Department., M. P. Shah Govt. Medical College, Jamnagar, Gujarat for Post Mortem examination with a history being found dead on the floor in a closed room with burnt mattress nearby. On enquiring, it was found out that he was a chronic chain smoker living alone, working as a contractor. Occasionally he used to take alcohol too. On that night he had dinner with some of his colleagues & slept alone.

### 2.1. Post mortem findings

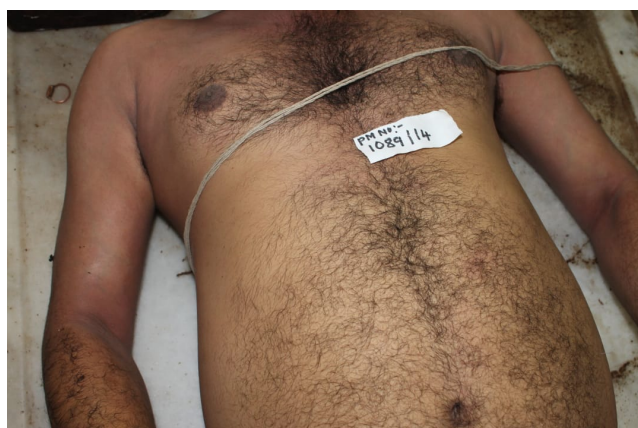The dead body was brought covered with a white cloth. On opening the cloth there was dead body of an identified Hindu male of about 38 years old. The worn clothes were one cream colour full sleeve shirt, white baniyan, black

\* Corresponding author.

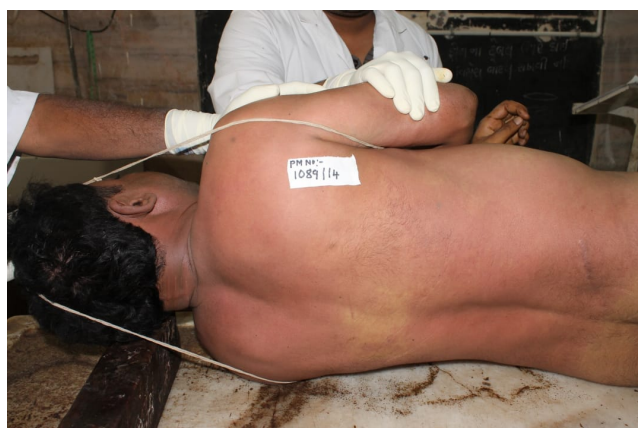E-mail address: [drgambhirsingh@gmail.com](mailto:drgambhirsingh@gmail.com) (O. G. Singh).

colour pant and brown colour underwear. A cotton thread (Janoi) was worn in the chest region. The body was average in built and nutrition (Figure 1). Both eyes were closed, mouth was closed and all other natural orifices were normal in appearance without any discharge. Black coloured smoke was seen around the nostrils and mouth. Cherry red post mortem staining was seen on dependent body parts and it was fixed. Rigor developed all over the body (Figure 2). Externally there was no any evidence of burns or injury.

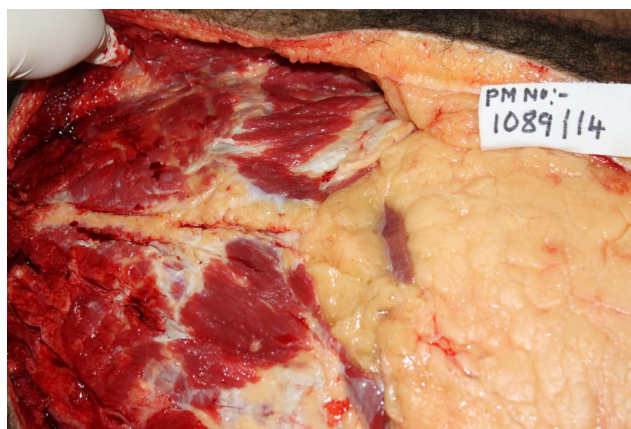A cherry-red discoloration of the mucous membranes, tissues and internal organs were seen. The lungs were congested with pink fluid blood and the trachea showed the black coloured soot particles adherent to the tracheal walls (Figures 3 and 4). There were no internal injuries found on the body. Blood was taken from the heart and preserved under a layer of liquid paraffin and sent for the estimation of the COHb concentration. After consideration of the autopsy findings, crime scene visits and investigation and COHb concentrations, the final cause of death was given as – “Died due to asphyxia on account of Carbon monoxide poisoning”. The manner of death was accidental in nature.



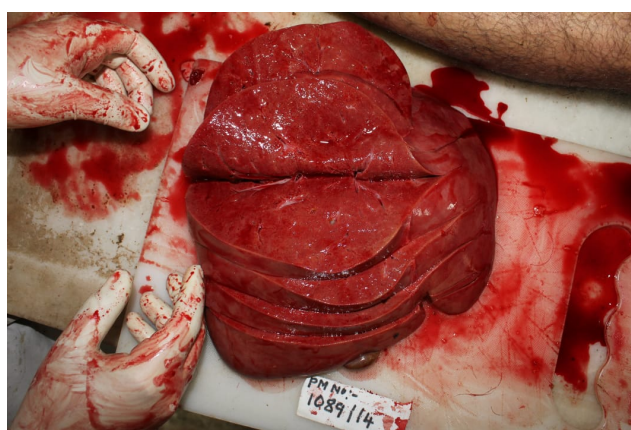**Fig. 1:** Average built & nutrition (Janoi on the chest)



**Fig. 2:** Cherry red Post mortem seen on back



**Fig. 3:** Cherry discoloration of tissues



**Fig. 4:** Cherry red discoloration of blood & viscera

### 3. Discussion

Accidental deaths by exposure to carbon monoxide gas in mines, during fire or incomplete combustion of wood, charcoal or coal in ill-ventilated rooms are major causes.<sup>4</sup> Occasionally accidental poisoning occurs now and then in domestic setups. More cases are seen during winter seasons. In a study conducted by Sikary AK<sup>8</sup> it was found that about 90% of such cases occurred during the winter season in India. Incidence is comparatively higher in young adults.<sup>9,10</sup> Previous studies also show that the main cause of fatal CO poisoning is due to the collection of this gas in an ill ventilated room.<sup>10-12</sup> Homicidal deaths are very uncommon. In the present case too, the person was found in the ill-ventilated room, lying on the floor with semi burnt mattress which might have burnt due to cigarette flame.

### 4. Conclusion

Public should be educated about the danger of CO gas poisoning in non-ventilated rooms. Special care must be taken when there is use of heating mechanisms during the

winter seasons. More prone people such as living single, single room accommodation, use of room heaters, blowers, fire pots, etc. should be educated about the possibility of CO poisoning. In flats, big buildings and public places use of smoke alarms and smoke detectors must be encouraged.

## 5. Conflict of Interest

The authors declare that there is no conflict of interest.

## 6. Source of Funding

None.


## References

- Reddy KN, Murty OP. The Essential of Forensic Medicine & Toxicology. JP Brothers; p. 443–6.
- Henn SA, Bell JL, Sussell AL, Konda S. Occupational carbon monoxide fatalities in the US from unintentional non-fire related exposures, 1992-2008. *Am J Ind Med.* 2013;56(11):1280–9. doi:10.1002/ajim.22226.
- Chang YC, Lee HY, Huang JL, Chiu CH, Chen CL, Wu CT, et al. Risk factors and outcome analysis in children with carbon monoxide poisoning. *Pediatr Neonatol.* 2017;58(2):171–7. doi:10.1016/j.pedneo.2016.03.007.
- Deniz T, Kandis H, Eroglu O, Gunes H, Saygun M, Kara IH, et al. Carbon monoxide poisoning cases presenting with non-specific symptoms. *Toxicol Ind Health.* 2017;33(1):53–60. doi:10.1177/0748233716660641.
- Bleecker ML. Carbon monoxide intoxication. In: Bleecker M, Lotti M, editors. Handbook of Clinical Neurology: Occupational Neurology. New York: Elsevier; 2015. p. 191–203.
- Cho CH, Chiu NC, Ho CS, Peng CC. Carbon monoxide poisoning in children. *Pediatr Neonatol.* 2008;49(4):121–5. doi:10.1016/S1875-9572(08)60026-1.
- Hampson NB, Weaver LK. Carbon monoxide poisoning: A new incidence for an old disease. *Undersea Hyperb Med.* 2007;34(3):163–8.
- Sikary AK, Dixit S, Murty OP. Fatal carbon monoxide poisoning: A lesson from a retrospective study at All India Institute of Medical Sciences, New Delhi. *J Family Med Prim Care.* 2017;6(4):791–4.
- Chand-Meena M. Accidental Death due to Carbon Monoxide: Case Report. *Int J Med Toxicol Forensic Med.* 2014;4(4):158–61.
- Nnoli M, Lebgbosi N, Chukwuonye I, Nwabuko O. Toxicological Investigation of Acute Carbon Monoxide Poisoning in Four Occupants of a Fuming Sport Utility Vehicle. *Iran J Toxicol.* 2014;7(23):973–6.
- Sharma S, Gupta R, Paul BS, Puri S, Garg S. Accidental carbon monoxide poisoning in our homes. *Indian J Crit Care Med.* 2009;13(3):169–70. doi:10.4103/0972-5229.58546.
- Behera C, Millo TM, Jaiswal A, Dogra TD. Accidental carbon monoxide poisoning during yagya for faith healing - a case report. *J Indian Med Assoc.* 2013;111(3):196–7.

## Author biography

**Kalpesh Chaudhari**, Assistant Professor

**Jitendra Rathod**, Associate Professor

**O Gambhir Singh**, Professor  <https://orcid.org/0000-0002-3955-3185>

**Cite this article:** Chaudhari K, Rathod J, Singh OG. An autopsy case of carbon monoxide poisoning: A case report. *IP Int J Forensic Med Toxicol Sci* 2023;8(1):44-46.