

Content available at: <https://www.ipinnovative.com/open-access-journals>

IP International Journal of Forensic Medicine and Toxicological Sciences

Journal homepage: <http://www.ijfmts.com/>

Case Report

Homicidal head injury with post-mortem burns: A case report

Anil Shandil¹, Sanjeev Kumar¹, Shiv Ranjan Kumar¹, Abhinav Abhay¹,
O Gambhir Singh^{1,*}

¹Dept. of Forensic Medicine, Patna Medical College and Hospital, Patna, Bihar, India



ARTICLE INFO

Article history:

Received 13-08-2023

Accepted 07-09-2023

Available online 25-10-2023

Keywords:

Blunt head injury

Postmortem burns

Manner of death

Homicide

ABSTRACT

Homicide by blunt head injury is relatively common as the most frequently involved organ when a blunt weapon is used to be the head. Head is one of the most vital parts in our body. Sometimes, such a case may be subjected to burns to hide the actual cause of death or to destroy the identity of the victim. Identification may be very difficult when there is involvement of head and face and this may be even more difficult when there is absence of body belongings and ornaments. Involvement of hands may destroy finger ridges too making it unsuitable for preservation of fingerprints. In this case report we examined a case of homicide by blunt head injury which was later on burned to destroy identity of the individual and to mislead the investigating officers in the determination of the cause of death.

This is an Open Access (OA) journal, and articles are distributed under the terms of the [Creative Commons Attribution-NonCommercial-ShareAlike 4.0 License](https://creativecommons.org/licenses/by-nc-sa/4.0/), which allows others to remix, tweak, and build upon the work non-commercially, as long as appropriate credit is given and the new creations are licensed under the identical terms.

For reprints contact: reprint@ipinnovative.com

1. Introduction

Most of the fatal head injuries are due to blunt forces and they may be homicidal or accidental in nature. When such cases are associated with burns, especially deep burns involving the head and face, identification becomes very difficult.¹ Such burns also may mutilate or destroy the evidence of bodily injuries. In such cases establishment of identity and fixation of cause of death may become very challenging for the medico-legal experts as the shreds of evidence are distorted or destroyed.²

Whenever a burnt unknown corpse is brought for a medico-legal examination the autopsy doctor must try his best level to establish the identity of the person, whether the burns are ante-mortem or post-mortem or the presence of any external or internal injury in the body. Determination of post-mortem or ante-mortem may be even difficult when the body is charred or decomposed.^{3,4} In the present case report we examined a case where the victim was murdered

by blunt head injury & latter on the body was burned to hide the identity and the cause of death.

2. Case History & Autopsy Finding

About 23-year-old unknown female body was brought for post-mortem examination. A white and red design cloth covered the dead body. On opening the cloth, we found a partially burnt green colour kurta by the side of the body. A greyish-blue color bra was also seen on the backside of the body. All clothes were partially burned and soiled with mud. A black colour thread was seen tied around the right ankle. The body was lean and thin & cold in temperature and soiled with mud at places. (Figures 1 and 2).

Both upper and lower limbs were in slightly flexed condition at their respective joints however presence of rigor mortis and post-mortem staining could not be ruled out due to the presence of burn effects.

The external appearance of the face is distorted & unidentifiable due to the effects of burns. Both eyes were closed, the mouth was slightly open and the tongue was

* Corresponding author.

E-mail address: drgambhirsingh@gmail.com (O. G. Singh).



Fig. 1: Superficial to deep burns

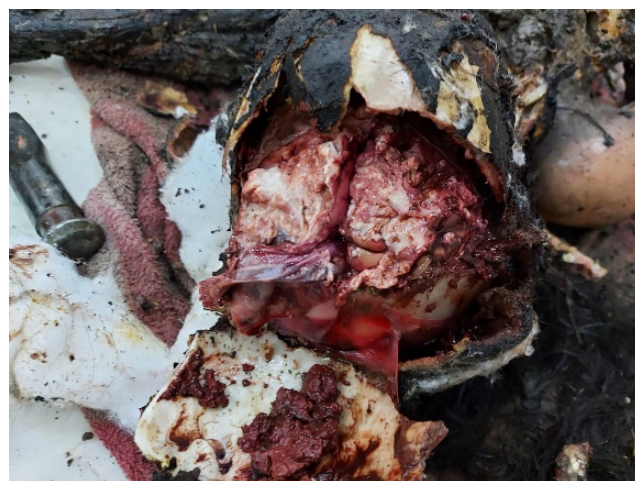

Fig. 4: Torn dura with Extra-dural hemorrhage



Fig. 2: Partially burnt clothes seen by the side

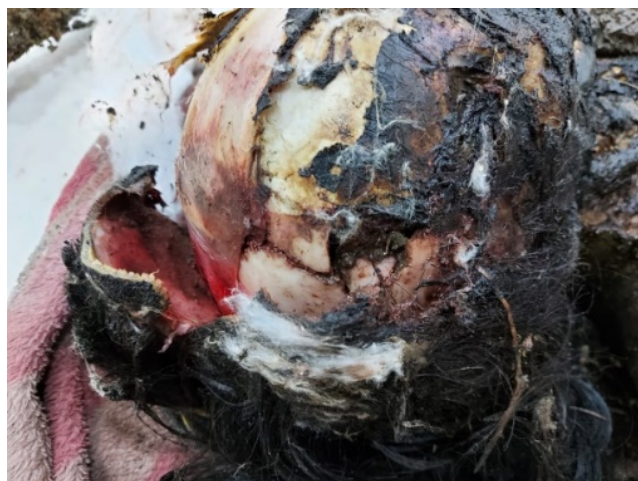

Fig. 3: Depressed fracture of skull

inside. Superficial and deep burns were seen almost all over the body except in a few places on the right shoulder and right leg. Peeling of epidermis along with blackish discoloration seen all over the body due to burns. The scalp and other body hairs showed singeing effects due to burns. Muscles and bone-deep burns were seen on the head & face, chest, abdomen, and pelvic region up to the lower portion of both knees. There was no soot particle deposition in the trachea. Ribs and sternum also charred deep to underlying lungs and heart. The abdominal cavity showed deep burns involving portions of the stomach and intestine. Pelvic organs too showed burn effects. The uterus is empty, normal in shape and size but congested.

There was a depressed comminuted fracture over the parieto-temporal region on both sides. It was about 4 X 3 cm in size. The fractured margins were irregular and stained with blood (Figure 3). On removing the scalp tissues the underlying occipital region showed the presence of scalp hematoma and the fracture lines extended into the occipital bone. The presence of other scalp injuries couldn't be ruled out due to burn effects. The dura mater was found to be torn with extradural hemorrhages seen over the right parieto-temporal regions. The underlying brain matter showed contusions and lacerations (Figure 4).

Available viscera preserved for chemical analysis. The recovered burnt clothes were also preserved for further investigation. Teeth preserved for DNA analysis. Cotton swabs from the vagina, cervix & uterine cavity were preserved to rule out the possibility of sexual intercourse. The cause of death was given as – “Died due to shock on account of blunt head injury”.

3. Discussion

Homicide by blunt head injury is common as the head is the target in the majority of the cases.¹ This is especially

true when blunt weapons are used. Sometimes such a case may be seen along with a post-mortem burn with a motive of destroying the identity of the individual or to mislead the actual cause of death. It is a real challenge for a medico-legal expert in such cases. Sometimes, it would be very difficult to differentiate ante-mortem burns from post-mortem burns.^{5,6} In the present case, there were no lines of redness at the demarcated junctions between burnt and unburnt areas. Blood was not cherry red in colour and there were no soot particles in the trachea. All these findings go in favour of post-mortem nature of the burns in the present case.

As the head and face portion were burnt almost deep it was not possible to establish the identity of the victim.^{7,8} Even fingerprints were not possible as both hands were also charred. Almost all worn clothes were involved in the burns except a few remains as stated above and so they were not helpful in the establishment of the identity of the victim. In such cases examination of teeth including DNA analysis is useful.⁷⁻⁹

4. Conclusion

Though burns may destroy or mislead the actual cause of death a careful post-mortem examination will definitely unveil the fact. One must be careful suspicion of foul play especially in unknown dead body with widespread deep burns. An attempt must be done to establish ante-mortem nature of the burns. If features of ante-mortem burns are missing then care must be taken to look for some other cause of death.

5. Source of Funding

None.

6. Conflict of Interest

None.

References

1. Mohanty S, Mohanty MK, Panigrahi MK, Das SK. Fatal head injury in homicidal victims. *Med Sci Law*. 2005;45(3):244–52.
2. Malik AA. Problems in the diagnosis of the causes of death in burned bodies. *J Forensic Sci Soc*. 1971;11:21–8. doi:10.1016/s0015-7368(71)70620-3.
3. Krishna K, Kumar A, Bhardwaj DN, Vidua RK. Recovery of Human Skeletal Remains - Various Issues During Medico-Legal Investigation. *Braz J Forensic Sci Med Law Bioeth*. 2013;2(2):113–35.
4. Tümer AR, Akçan R, Karacaoğlu E, Balseven-Odabaşı A, Keten A, Kanburoğlu C. Postmortem burning of the corpses following homicide. *Jr of Forensic Leg Med*. 2012;19(4):223–8.
5. Fanton L, Jdeed K, Tilhet-Coartet S, Malicier D. Criminal burning. *Forensic Sci Int*. 2006;158(2-3):87–93.
6. Alexandri M, Koukoulis AN, Tsellou M, Papadodima S. A burned body with a shotgun head injury found on an “altar” made of banknotes: A case report from Greece and brief review of the literature. *Legal Medicine*. 101882;51:101882. doi:10.1016/j.legalmed.2021.101882.
7. Solheim T, Andersen L, Juhl M, Borrman H. Odontological identification of fire victims -potentialities and limitations. *Int J Legal Med*. 1995;107:229–34.
8. Bohnert M, Werner CR, Pollak S. Problems associated with the diagnosis of vitality in burned bodies. *Forensic Science Int*. 2003;135(3):197–205.
9. Reddy KSN, Murty OP. The essentials of forensic medicine and toxicology. 34th ed. New Delhi: Jaypee Brothers Medical Publishers; 2022. p. 301–3.


Author biography

Anil Shandil, Associate Professor

Sanjeev Kumar, Post Graduate Student

Shiv Ranjan Kumar, Assistant Professor

Abhinav Abhay, Post Graduate Student

O Gambhir Singh, Professor  <https://orcid.org/0000-0002-3955-3185>

Cite this article: Shandil A, Kumar S, Kumar SR, Abhay A, Singh OG. Homicidal head injury with post-mortem burns: A case report. *IP Int J Forensic Med Toxicol Sci* 2023;8(3):118-120.